

SHORT COMMUNICATION

Scratching the Surface: A Paraneoplastic Pruritus Phenomenon in a Mediastinal Mass

Devine Thomas DO¹, Yousef Salem BS², Naser Asfoor BA³, Mohamad Jabin BS⁴, Mojahed M. K. Shalabi MD^{1,4}, Stephen E. Baker MD¹, Shovendra Gautam MD MBA¹

¹ Baylor Scott & White All Saints Medical Center, Fort Worth, Texas

² University of Texas Health Science Center at San Antonio, San Antonio, Texas

³ Texas College of Osteopathic Medicine, Fort Worth, Texas

⁴ Texas A&M Health Science Center, Temple, Texas

A 35-year-old female presented to her dermatologist with generalized pruritus. She was prescribed Hydroxyzine with minimal relief but did not return to her dermatologist for follow-up. After 2 years from the initial onset of her pruritic symptoms she began to develop progressively worsening dyspnea, and went to see her primary care physician. Her primary care provider ordered a chest x-ray, which revealed a large mediastinal mass, prompting an urgent referral to the emergency department.

A review of systems was negative for classic B-symptoms such as fevers, chills, weight loss, as well as any skin lesions, rash, or pain. Overall, the patient appeared well, with the physical exam showing bilaterally decreased breath sounds and excoriations on her abdomen and extremities. (**Figure 1**) Her vital signs were within normal limits.

A computed tomography (CT) scan revealed a large mediastinal mass encasing the majority of great vessels, including the upper aorta and compressing the brachiocephalic veins and superior vena cava (SVC). (**Figure 2**) Further workup confirmed the diagnosis of Hodgkin's lymphoma and the appropriate

therapy was initiated. Treatment of her tumor resulted in symptomatic improvement, strongly suggesting a paraneoplastic etiology.

Hodgkin's lymphoma typically progresses indolently, often presenting with asymptomatic lymphadenopathy as the most common sign. Constitutional symptoms such as fever, chills, and night sweats occur in less than half of cases. Pruritus is even rarer but can serve as an ominous sign of a poorer prognosis.¹ In this case, the patient's symptoms were relieved with treatment of the malignancy.

Pruritus is an extremely common nonspecific finding in numerous conditions, including benign dermatoses like eczema or irritant dermatitis. Patients presenting with chronic pruritus without a primary skin disorder require a thorough history and physical examination to identify any underlying systemic illness.² Symptoms refractory to anti-pruritic therapy should increase suspicion for serious underlying pathology, such as uremia secondary to renal failure, iron deficiency anemia, polycythemia, hyperthyroidism, Hepatitis C, HIV, or occult

SKIN

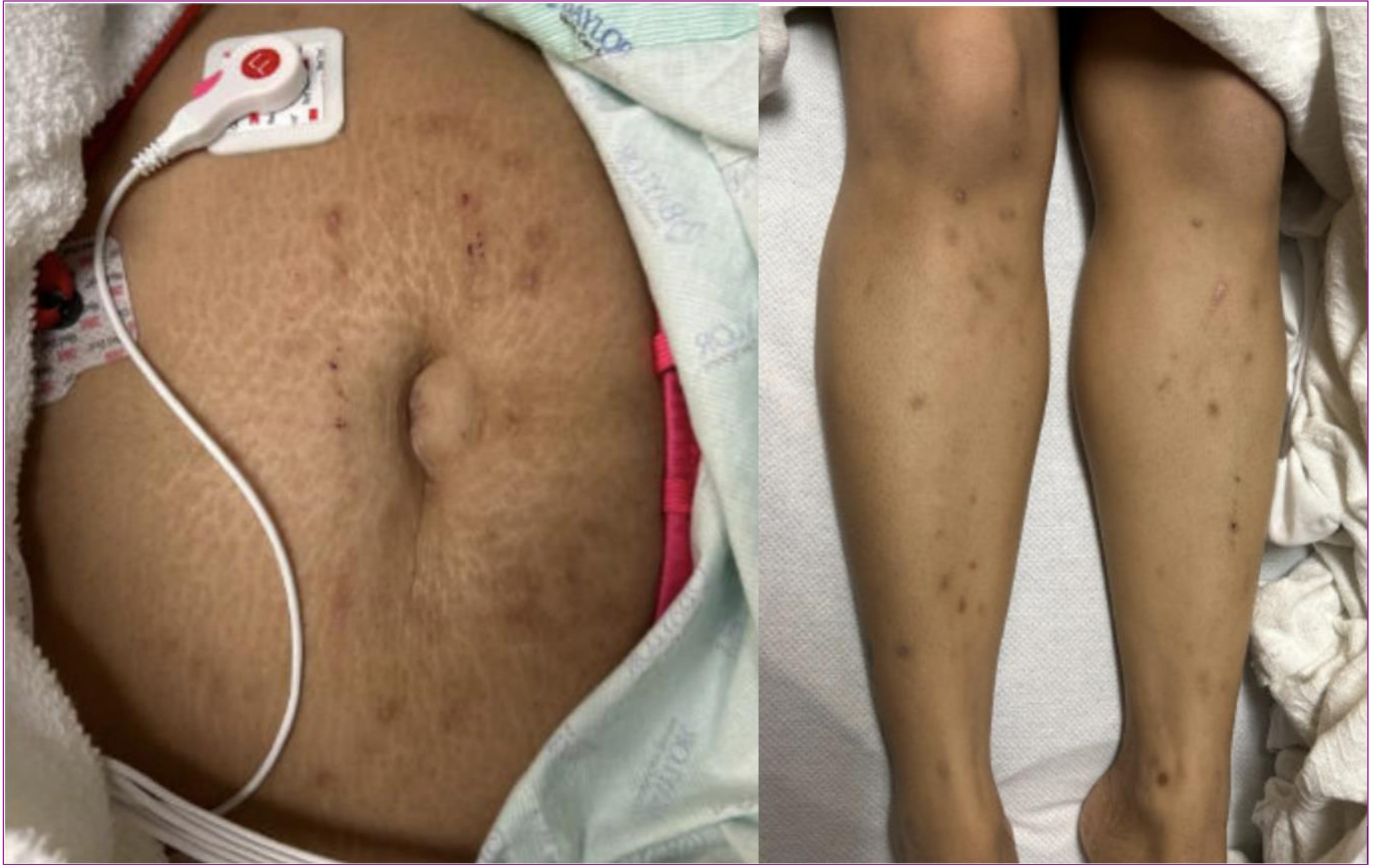


Figure 1. Physical exam showing excoriations over the abdomen (Left) and lower extremities (Right) on physical exam.

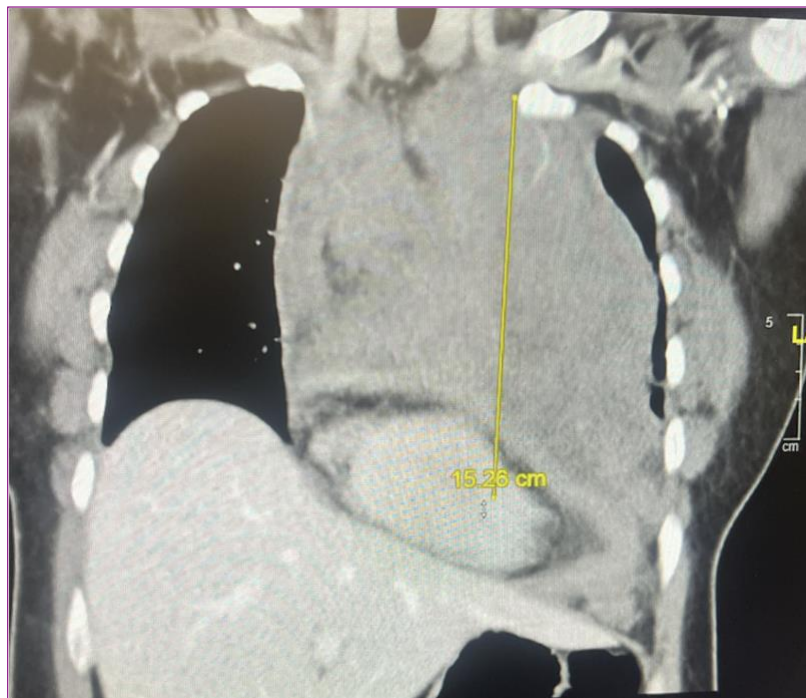


Figure 2. Computed Tomography Scan displaying a large (15.28 cm) mass in the mediastinum.

May 2024 Volume 8 Issue 3

malignancy may be involved.^{3,4} When appropriate, common relevant laboratory testing can include a complete metabolic panel (CMP), complete blood count (CBC), HIV testing, and thyroid function tests, as well as a chest radiograph.⁵ In cases like this one, involving Hodgkin's lymphoma, urgent consultation with an oncologist for initiation of anti-cancer therapy is essential.⁶ In similar cases seen in both children and adults, patients suffering from intractable pruritus improved vastly with initiation of chemotherapy for lymphoma.^{7,8}

Even in the absence of systemic disease, the impact of chronic pruritus on quality of life should not be underestimated, and appropriate treatment should be provided.⁶ Common treatment options include oral therapies such as antihistamines, anticonvulsants, and antidepressants as well as topical forms of steroids, capsaicin, and calcineurin inhibitors.² Continuing research into the specific cytokines that may cause lymphoma-associated pruritus may eventually result in targeted therapies for palliation in these patients.⁹

Conflict of Interest Disclosures: None

Funding: None

Corresponding Author:

Mojahed Shalabi
2401 S 31st St, Temple, TX, USA 76508
Email: ShalabiMojahed@gmail.com

References:

1. Gobbi PG, Attardo-Parrinello G, Lattanzio G, Rizzo SC, Ascari E. Severe pruritus should be a B-symptom in Hodgkin's disease. *Cancer*. 1983;51(10):1934-1936. doi:[10.1002/1097-0142\(19830515\)51:10<1934::aid-cnrcr2820511030>3.0.co;2-r](https://doi.org/10.1002/1097-0142(19830515)51:10<1934::aid-cnrcr2820511030>3.0.co;2-r)
2. Yosipovitch G, Bernhard JD. Chronic Pruritus. *New England Journal of Medicine*. 2013;368(17):1625-1634. doi:[10.1056/NEJMcp1208814](https://doi.org/10.1056/NEJMcp1208814)
3. Serling SLC, Leslie K, Maurer T. Approach to pruritus in the adult HIV-positive patient. *Semin Cutan Med Surg*. 2011;30(2):101-106. doi:[10.1016/j.sder.2011.04.004](https://doi.org/10.1016/j.sder.2011.04.004)
4. Maticic M, Poljak M, Lunder T, Renner-Sitar K, Stojanovic L. Lichen planus and other cutaneous manifestations in chronic hepatitis C: pre- and post-interferon-based treatment prevalence vary in a cohort of patients from low hepatitis C virus endemic area. *J Eur Acad Dermatol Venereol*. 2008;22(7):779-788. doi:[10.1111/j.1468-3083.2008.02676.x](https://doi.org/10.1111/j.1468-3083.2008.02676.x)
5. Kini SP, DeLong LK, Veledar E, McKenzie-Brown AM, Schaufele M, Chen SC. The impact of pruritus on quality of life: the skin equivalent of pain. *Arch Dermatol*. 2011;147(10):1153-1156. doi:[10.1001/archdermatol.2011.178](https://doi.org/10.1001/archdermatol.2011.178)
6. Ansell SM. Hodgkin Lymphoma: Diagnosis and Treatment. *Mayo Clin Proc*. 2015;90(11):1574-1583. doi:[10.1016/j.mayocp.2015.07.005](https://doi.org/10.1016/j.mayocp.2015.07.005)
7. Bartus CL, Parker SR. Hodgkin lymphoma presenting as generalized pruritus in an adolescent. *Cutis*. 2011;87(4):169-172.
8. Benn G, Adidam S, Ali A, Taddesse-Heath L. A Case of Classical Hodgkin's Lymphoma Presenting With Intractable Pruritus. *Cureus*. 2021;13(11):e19854. Published 2021 Nov 24. doi:[10.7759/cureus.19854](https://doi.org/10.7759/cureus.19854)
9. Wen X, Yu H, Zhang L, et al. The relationship and clinical significance of serum cytokine expression level and skin pruritus in patients with Hodgkin lymphoma and angioimmunoblastic T-cell lymphoma. *Int Immunopharmacol*. Published online March 14, 2024. doi:[10.1016/j.intimp.2024.111777](https://doi.org/10.1016/j.intimp.2024.111777)