

## BRIEF ARTICLES

**Mycobacterium marinum Infection in a Post-Katrina Carpenter: The Importance of Exposures**

Zachary P. Nahmias MD<sup>a</sup>, Tina Hsu BA<sup>b</sup>, C. Brad Bledsoe MD<sup>c</sup>, Robert Skinner, MD<sup>d</sup> Rebecca Todd-Bell<sup>e</sup>

<sup>a</sup>Division of Dermatology, Washington University School of Medicine, St. Louis, MO

<sup>b</sup>Washington University School of Medicine, St. Louis, MO

<sup>c</sup>Advanced Dermatology and Skin Cancer Associates, Memphis, TN

<sup>d</sup>Division of Dermatology, University of Tennessee Health Science Center, Memphis, TN

<sup>e</sup>Central Dermatology Center, Chapel Hill, NC

## ABSTRACT

Microbial exposure patterns are often altered as the result of natural disasters, causing certain infections with a normally characteristic epidemiologic profile to be seen in unfamiliar contexts. This phenomenon was well-demonstrated in New Orleans following the devastation caused by Hurricane Katrina, with many relief workers experiencing unusual infections. We report a case of cutaneous *Mycobacterium marinum* infection in a carpenter following participation in a Hurricane Katrina reconstruction project.

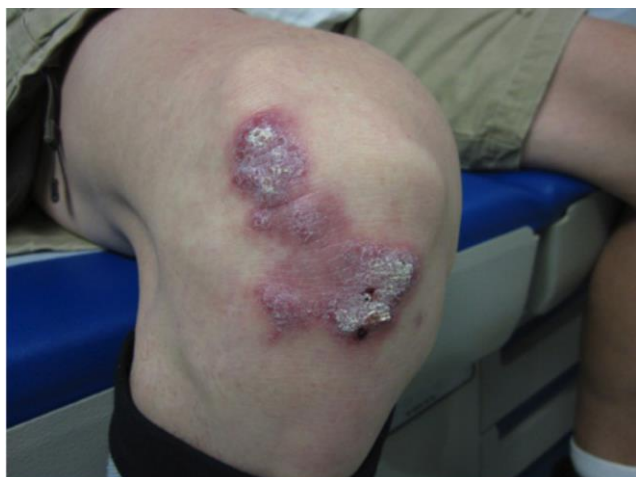## INTRODUCTION

*Mycobacterium marinum*, typically found in salt and fresh water environments, is a bacterium that can infect the skin after puncture and generally manifests as a localized granuloma or lymphangitis in a sporotrichotic distribution.<sup>1</sup> *M. marinum* infection is typically seen in patients who have a history of exposure to aquariums. We report a unique case of *M. marinum* that developed on the right knee following participation in a Hurricane Katrina reconstruction project.

## CASE REPORT

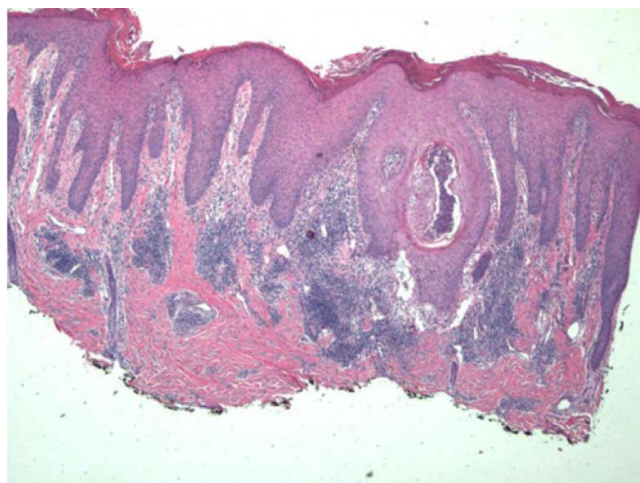
A 47-year-old Hispanic male presented with a three-year history of an asymptomatic hyperkeratotic pink plaque on the right knee that developed while doing carpentry work in post-Katrina New Orleans. The patient noted the lesion to be unresponsive to over-the-counter topical steroids and antifungal medications. He had no other medical history. Other than the lesion, physical exam findings were negative (Figure 1). A skin biopsy was performed on the lesion and sent for histologic examination with H&E staining, as well as fungal and mycobacterial

tissue cultures. H&E staining demonstrated pseudoepitheliomatous hyperplasia with nodular chronic inflammation to the deep dermis with granulomatous perifolliculitis (Figure 2). No fungal elements were



**Figure 1.** The patient presented with an ivory-white and pink hyperkeratotic plaque on the right knee.

observed on PAS staining. Fungal culture was negative at 4 weeks. Mycobacterial culture demonstrated *M. marinum* at 4 weeks.



**Figure 2.** There is pseudoepitheliomatous hyperplasia with chronic nodular inflammation to the deep dermis with granulomatous perifolliculitis. These findings are consistent with infection due to *M. marinum*. (H&E, 5x magnification).

## INTRODUCTION

Natural disasters create a unique exposure to rarely seen infectious agents. Among Hurricane Katrina evacuees and rescue workers, there were at least 30 cases of methicillin-resistant *Staphylococcus aureus* infection and 24 cases of hurricane-associated *Vibrio vulnificus* and *V. parahaemolyticus* wound infections reported. Six of these infections resulted in death.<sup>2</sup> A 26-year-old relief worker with a three-month history of skin lesions, pulmonary symptoms, ataxia, and left-sided weakness was diagnosed with blastomycosis.<sup>3</sup> Following a visit to her flooded New Orleans home, an 85-year-old woman undergoing treatment with azathioprine for autoimmune hepatitis developed fever, chills, mild hypoxia, and

dysuria, and she was subsequently diagnosed with urosepsis caused by *Buldivicia aquatica*. This was the first reported case of *B. aquatica* infection in a patient.<sup>4</sup>

When working up patients following natural disasters, clinicians should be mindful of alterations in the environment, just as they would a patient with a significant travel or occupational exposure history. Following natural disasters, stagnant water, destroyed man-made and natural materials, and non-native bacteria may be more prevalent in the environment and pose a significant risk to relief workers and returning evacuees. Historically, cutaneous infection with *M. marinum* has been associated with people

who handle fish and those who work in aquariums.<sup>5</sup>

The course of infection is usually indolent but can occasionally follow a rapidly progressive course, resulting in sepsis. It is important to elicit a thorough history given the relative rarity of this condition. In the patient discussed above, exposure history was critical to broadening the differential diagnosis and workup to include cultures for less commonly encountered infectious agents along with routine bacterial and fungal stains and cultures. In addition to infections by *M. marinum*, infections by *V. vulnificus* and *V. parahaemolyticus* must also be considered in post-hurricane relief areas.<sup>6</sup> Use of minocycline, clarithromycin, and ethambutol has been described for the treatment of *M. marinum* infection; our patient cleared infection with an extended half-year course of minocycline. In the case of deep or widespread infection, surgical intervention may be needed in addition to medical therapy.<sup>4</sup>

**Conflict of Interest Disclosures:** None

**Funding:** None

**Corresponding Author:**

Zachary P. Nahmias, MD  
 Division of Dermatology  
 Washington University School of Medicine  
 660 South Euclid Avenue  
 Campus Box 8123  
 St. Louis, MO 63110  
 314-454-8622 (Office)  
 nahmias@wustl.edu

**References:**

1. Rallis E, Koumantaki-Mathioudaki E. Treatment of Mycobacterium marinum cutaneous infections. *Expert Opin Pharmacother.* 2007;8(1744-7666 (Electronic)):2965-2978.
2. Jablecki J, Norton SA, Keller R, et al. Infectious disease and dermatologic conditions in evacuees and rescue workers after hurricane Katrina - Multiple states, August-September, 2005. *J Am Med Assoc.* 2005;294(17):2158-2160.
3. Szeder V, Ortega-Gutierrez S, Frank M, Jaradeh SS. CNS blastomycosis in a young man working in fields after Hurricane Katrina. *Neurology.* 2007;68(20):1746-1747.
4. Corbin A, Delatte C, Besson S, et al. Budvicia aquatica sepsis in an immunocompromised patient following exposure to the aftermath of Hurricane Katrina. *J Med Microbiol.* 2007;56(8):1124-1125.
5. Nordén A, Linell F. A new type of pathogenic mycobacterium [4]. *Nature.* 1951;168(4280):826.
6. Rhoads J. Post-Hurricane Katrina challenge: Vibrio vulnificus. *J Am Acad Nurse Pract.* 2006;18(7):318-324. doi:10.1111/j.1745-7599.2006.00139.x.