

## BRIEF ARTICLE

**Intralesional Kenalog Injections for Recurrent Cutaneous Rosai-Dorfman Disease (RDD) in the Lower Extremity**

Victoria Jiminez<sup>1</sup>, Lawangeen Zeb, MD<sup>2</sup>, Anna Gray, MD<sup>3</sup>, Lauren Van Duyn Graham, MD, PhD<sup>2</sup>

<sup>1</sup> Heersink School of Medicine, University of Alabama at Birmingham, Birmingham, AL

<sup>2</sup> Department of Dermatology, University of Alabama at Birmingham, Birmingham, AL

<sup>3</sup> SkinDX Dermatopathology Group, Birmingham, AL

**ABSTRACT**

Rosai-Dorfman disease (RDD) is a rare disorder of histiocytic origin with nodal, extranodal, and cutaneous classifications often presenting as eruptive rashes, most commonly affecting the face, trunk, and thigh. Due to its rarity, no consensus exists regarding standard of care for these lesions, as most knowledge regarding treatment is provided by case reports. To our knowledge, we report the first case of a patient with a recurrent lower extremity mass consistent with cutaneous RDD, despite surgical excision and topical steroids treatment. A 51-year-old female presented with recurrent RDD after failed treatment with clobetasol ointment and surgical excision at an outside practice. Examination revealed violaceous plaques with overlying scale, without lymphadenopathy. With the failure of the previous excision, the patient was prescribed 5 mg/ml intralesional Kenalog (ILK) injections to suppress inflammation of the lesion. She experienced improved clinical response to treatment and remission of active disease with residual post-inflammatory hyperpigmentation at 10 months after two rounds of injections, although the patient reported vast improvement at 5 months as well. Treatment of RDD is difficult due to its rarity, hindering clinical trial development. Therapeutics reported to be efficacious include topical, intralesional, and systemic steroids, retinoids, methotrexate, chemotherapy, cryotherapy, phototherapy, and radiation. Clinical management is variable and often requires multiple forms of treatment on a case-to-case basis, highlighting the need for larger clinical studies to establish a standard of care. Our case poses interest in the use of ILK for RDD and should be considered in recurrent cases after prior surgical excision.

**INTRODUCTION**

Rosai-Dorfman disease (RDD) is a rare disorder of histiocytic origin with nodal, extranodal, and cutaneous classifications. Due to its rarity, most knowledge surrounding RDD is from published case reports.

The hallmark of diagnosis is confirmation histologically with positive expression of S-100 and negative expression of CD1a protein in the cytoplasm of “Rosai-Dorfman cell” histiocytes.<sup>1</sup> Neutrophils and lymphocytes are often present and can be engulfed by these histiocytes, a phenomenon called emperipolesis.<sup>1</sup>

Currently, no consensus exists regarding standard of treatment for RDD lesions. Commonly reported modes of intervention include steroidal and systemic therapies, surgical excision, and laser therapy.<sup>2</sup>

There are few cases in the literature consisting of RDD local recurrence after surgical excision. To our knowledge, we report a unique case of a 51-year-old female who presented with a recurring right lower leg mass consistent with cutaneous RDD, despite surgical excision and topical steroids.

## CASE REPORT

A 51-year-old female presented for a second opinion evaluation of cutaneous Rosai-Dorfman disease. Approximately 18 months ago, the patient reported the onset of a right lower leg rash that initially appeared to resemble an insect bite, then grew into a large, circular plaque that was sore to palpation. A punch biopsy of the right distal calf was obtained at that time and revealed Rosai-Dorfman disease upon staining, with negative stains for fungal hyphae, acid fast bacilli, and spirochete microorganisms.

The patient was treated with clobetasol ointment without improvement. The lesion was then surgically excised. Pathology revealed a nodular infiltrate of large histiocytes with eosinophilic cytoplasm containing focal inflammatory cells, consistent with emperipolesis. Admixed collections of neutrophils, plasma cells, and lymphocytes were also present and can be seen in **Figure 1**. A positive S-100 stain and negative CD1a stain confirmed the diagnosis of RDD.

At our institution, the patient presented with a recent history of local recurrence, larger than the original lesion and around the previous

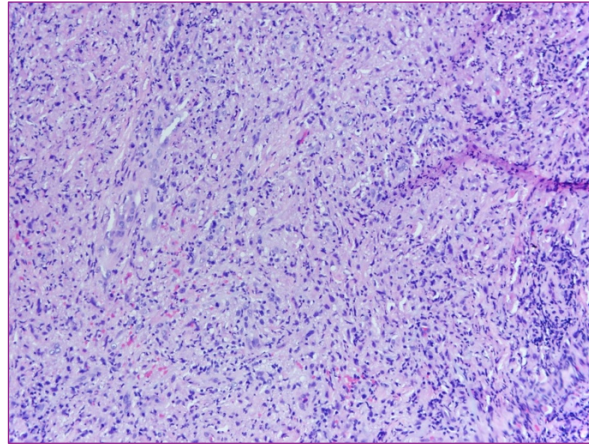
excision site. Examination revealed violaceous plaques with overlying scale on the posterior right leg, seen in **Figure 2**. No lymphadenopathy was observed. With the failure of the previous excision, the patient was prescribed 5 mg/ml intralesional Kenalog injections to suppress inflammation of the lesion. **Figure 3** shows clinical response to treatment and remission of active disease with residual post-inflammatory hyperpigmentation at 10 months after two rounds of injections, although the patient reported vast improvement at 5 months as well.

## DISCUSSION

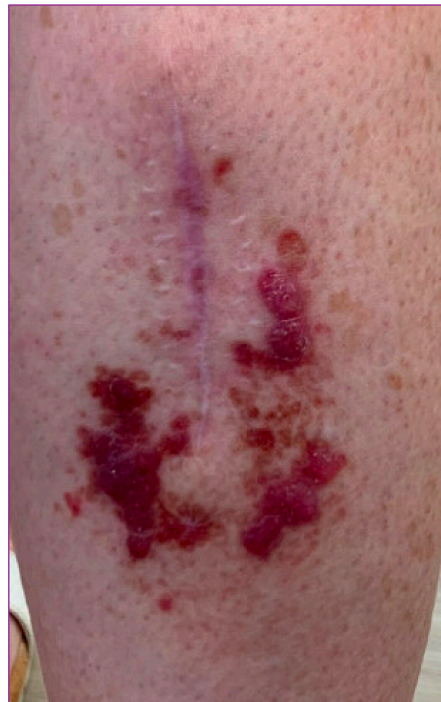Cutaneous RDD is rare and affects females of East-Asian, Caucasian, and African populations most commonly.<sup>3</sup> Cutaneous manifestations have most frequently been reported on the face, trunk, and thigh.<sup>2</sup> To our knowledge, few cases of recurrent cutaneous RDD have been reported on the extremities after surgical excision.

Etiology of this condition is unknown, but has been hypothesized to have autoimmune, neoplastic, genetic, infectious, and inflammatory mechanisms.<sup>2</sup> Most frequently, systemic RDD consists of bilateral lymphadenopathy, fever, polyclonal gammaglobulinemia, and immunologic dysfunction.<sup>1</sup> It is estimated that greater than 40% of RDD cases have extranodal involvement, with 10% of cases having cutaneous disease.<sup>1</sup>

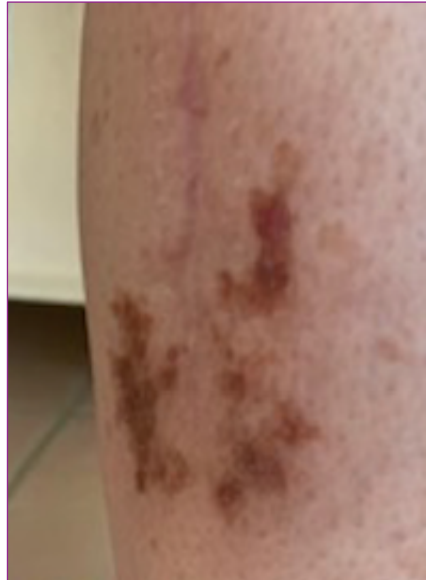Treatment is difficult due to its rarity, hindering clinical trial development. Some cases have reported spontaneous regression with no treatment intervention. Other forms that have been suggested including topical, intralesional, and systemic steroids, imiquimod, thalidomide, isotretinoin,



**Figure 1.** Leukocytic infiltrate of patient's RDD lesion at 20x magnification



**Figure 2.** Recurrence of RDD surrounding previous excision site



**Figure 3.** Improvement of RDD following 2 rounds of ILK injections

methotrexate, dapsone, vincristine, acitretin, interferon, rituximab, chemotherapy, cryotherapy, and radiation therapy.<sup>2,4</sup> Several of these therapies have been reported for cutaneous RDD to be helpful, with effects varying from mild to total improvement.<sup>4</sup> Localized disease has been treated with surgical excision or cryotherapy.<sup>4</sup> Topical and intralesional corticosteroids and topical imiquimod have shown beneficial effects in some cases.<sup>4</sup>

A 2019 review of every known case of cutaneous RDD found steroids to be the least effective treatment.<sup>3</sup> In the setting of refractory and aggressive disease, they report high dose thalidomide, vincristine, methotrexate, acitretin, isotretinoid, and dapsone to be the most efficacious in remission.<sup>3</sup> This finding was contradictory in the case of our patient, who saw marked improvement of her recurrent lesion with steroid injections.

Two cases have utilized treatment with methotrexate (MTX) 15 mg per week adjunct to triamcinolone injections, achieving total and partial remission, respectively.<sup>4</sup>

Intralesional MTX injection followed by 10 mg oral MTX weekly demonstrated 50% improvement of disease in one patient, with subsequent 75% improvement with increased dosage and no reported adverse effects.<sup>5</sup> Use of intralesional agents in our case and other cases has been shown to be efficacious and cause minimal to no side effects for patients.

Gameiro, et al. observed rapid remission of cutaneous RDD when placed on thalidomide, based on previous reports of successful therapy, while others have seen no improvement.<sup>6,7</sup> In an unsuccessful case of thalidomide treatment, subsequent (ALA)-photodynamic therapy with 20% ALA gel applied topically was reported to show significant improvement in size and pigment of the plaque.<sup>7</sup> In 2020, the first successful report of cutaneous RDD remission using pulsed dye laser (PDL) observed rapid improvement of an erythematous plaque located on the patient's philtrum.<sup>8</sup> While the exact mechanism for this is unclear, PDL destroys dermal vasculature and interferes with angiogenesis that may play a role in hindering inflammatory pathways and

abnormal histiocyte proliferation in cutaneous RDD.<sup>8</sup>

Similar to our patient, one case in the literature describes a recurrent, invasive RDD of the parotid gland after surgical excision.<sup>2</sup> Oral steroids were initiated and the patient underwent a total parotidectomy, eventually achieving no residual disease at 3 months follow up.<sup>2</sup> Another case of recurrent RDD after surgical excision in the upper arm saw improvement with subsequent acitretin use. With recurrent and aggressive disease, the literature reports remission most frequently in the forms of systemic therapy or more invasive surgical excisions.<sup>9</sup>

## CONCLUSION

We report success in the use of post-surgical recurrent RDD with intralesional Kenalog injections. Clinical management of RDD is variable and often requires multiple forms of treatment on a case-to-case basis, highlighting the need for larger clinical studies to establish a standard of care and definitive management strategies to avoid multiple invasive treatments for this patient population.

**Conflict of Interest Disclosures:** None

**Funding:** None

### Corresponding Author:

Lauren Graham, MD, PhD  
500 22nd St S, Suite 3400, Birmingham, Alabama  
35233  
Email: [lvgraham@uabmc.edu](mailto:lvgraham@uabmc.edu)

### References:

- Al-Khateeb TH. Cutaneous Rosai-Dorfman Disease of the Face: A Comprehensive Literature Review and Case Report. *J Oral Maxillofac Surg.* 2016;74(3):528-540. doi:10.1016/j.joms.2015.09.017
- Karami R, Ghieh F, Baroud J, Abu Sittah G. Rosai-Dorfman Disease: Cutaneous and Parotid Involvement. *Ann Plast Surg.* 2019;82(6):639-641. doi:10.1097/SAP.0000000000001794
- Ahmed A, Crowson N, Magro CM. A comprehensive assessment of cutaneous Rosai-Dorfman disease. *Ann Diagn Pathol.* 2019;40:166-173. doi:10.1016/j.anndiagpath.2019.02.004
- Gawdzik A, Ziarkiewicz-Wróblewska B, Chlebicka I, Jankowska-Konsur A, Szepietowski JC, Maj J. Cutaneous Rosai-Dorfman Disease: A Treatment Challenge. *Dermatol Ther (Heidelb).* 2021;11(4):1443-1448. doi:10.1007/s13555-021-00557-1
- Subash JJ, Kesty C, Kesty KR, Asgari M, Jorizzo J. Low-dose weekly methotrexate used to treat cutaneous Rosai-Dorfman disease. *Clin Exp Dermatol.* 2018;43(7):849-851. doi:10.1111/ced.13665
- Gameiro A, Gouveia M, Cardoso JC, Tellechea O. Histological variability and the importance of clinicopathological correlation in cutaneous Rosai-Dorfman disease. *An Bras Dermatol.* 2016;91(5):634-637. doi:10.1590/abd1806-4841.20164477
- Sun L, Shi J, Su Z, Zhang M, Lu Y. Successful treatment of Rosai-Dorfman disease using ALA-PDT. *Photodiagnosis Photodyn Ther.* 2018;21:128-129. doi:10.1016/j.pdpdt.2017.11.014
- Park AY, Lee HJ, Hong SA, Kim JE. Successful Treatment of Cutaneous Rosai-Dorfman Disease With Pulsed Dye Laser. *Dermatol Surg.* 2020;46(2):286-289. doi:10.1097/DSS.0000000000001798
- Fening K, Bechtel M, Peters S, Zirwas M, Darabi K. Cutaneous rosai-dorfman disease persisting after surgical excision: report of a case treated with acitretin. *J Clin Aesthet Dermatol.* 2010;3(9):34-36.