

## BRIEF ARTICLE

## Drug-Induced Erythema Annulare Centrifugum After Dupilumab Therapy: A Case Report

Simran Kalsi MS<sup>1</sup>, Santana VanDyke MD<sup>2</sup>, Julia Barker MD<sup>2</sup>, Joseph Pierson MD<sup>2</sup>

<sup>1</sup> Larner College of Medicine at the University of Vermont, Burlington, VT

<sup>2</sup> University of Vermont Medical Center, Department of Medicine, Division of Dermatology, Burlington, VT

### ABSTRACT

**Introduction:** Dupilumab is a fully human monoclonal antibody therapy FDA-approved to treat moderate-to-severe atopic dermatitis (AD) by interrupting the pro-inflammatory signaling pathway of interleukins 4 and 13. Common side effects of dupilumab include injection-site reactions, ophthalmic complications, and upper respiratory infections. We discuss the necessity for early recognition and management of dupilumab-induced EAC which has not been previously reported as a potential adverse effect.

**Case Report:** A 48-year-old woman began treatment with dupilumab for severe AD and subsequently presented with a 3-month history of erythematous annular plaques with trailing scale on the trunk and extremities. She failed treatment with topical corticosteroids as well as topical and oral antifungals prior to being diagnosed with biopsy-confirmed erythema annulare centrifugum (EAC). The condition worsened after replacing dupilumab with tralokinumab but resolved after discontinuation of the drugs and has remained clear since.

**Conclusion:** EAC is a reactive erythema that typically presents as expanding annular papules and plaques with central clearing and in some cases, trailing scale at the rim of the lesions. There are currently no reports in the literature describing the development of EAC secondary to dupilumab. Clinicians should be aware that EAC may be a potential adverse effect of dupilumab.

### INTRODUCTION

Dupilumab is a fully human monoclonal antibody therapy approved by the Food and Drug Administration (FDA) to treat moderate-to-severe atopic dermatitis (AD) in adults and children.<sup>1</sup> The drug binds to interleukin 4R $\alpha$  (IL-4R $\alpha$ ) in the pro-inflammatory signaling pathway of interleukins 4 and 13 (IL-4/IL-13) to inhibit Th2 cell differentiation.<sup>2</sup> The drug is generally well-tolerated with injection-site reaction being the most reported adverse effect. Other common adverse effects include

upper respiratory tract infection, ophthalmic complications, alopecia, hypereosinophilia, arthritis, development of psoriatic plaques, and progression of cutaneous T-cell lymphoma exacerbation.<sup>3-5</sup>

Development of EAC after initiating treatment with dupilumab for the treatment of AD has not previously been reported in the literature. Herein, we present the case of a patient who began treatment with dupilumab for severe AD and then developed EAC which resolved after discontinuation of the drug.

## CASE REPORT

A 48-year-old woman with a history of AD, allergic rhinitis, asthma, and prurigo nodularis presented to the outpatient dermatology clinic for management of severe atopic dermatitis. She had failed treatment with topical corticosteroids as well as a three-month trial of methotrexate. Dupilumab was subsequently initiated, and she reported an improvement in control of both AD and asthma symptoms with a reduced need for topical corticosteroids and rescue inhalers.

Approximately three months after starting dupilumab, she developed erythematous annular plaques with trailing scale on the trunk and extremities which was unresponsive to topical corticosteroids (**Figure 1A**). An outside physician prescribed oral fluconazole without improvement. Skin scraping was negative for fungal organisms on KOH prep, but due to concern for tinea corporis, she was started on topical clotrimazole cream. The patient was not adherent to the topical treatment regimen, but the rash on the abdomen eventually resolved. However, she then developed a similar rash on her thighs that was also unresponsive to antifungal treatment. Punch biopsy of the right thigh was subsequently performed. Histopathology demonstrated superficial perivascular dermatitis with spongiosis and areas of mounded parakeratosis (**Figure 2**). Given the classic appearance of the rash and supporting histopathologic findings, she was diagnosed with erythema annulare centrifugum (EAC).

Treatment with topical corticosteroids was continued and tacrolimus ointment was trialed without improvement. Given the timing of the rash and lack of improvement with first-line therapies, there was concern for a drug-induced process. She was subsequently

switched from dupilumab to tralokinumab. However, she developed worsening EAC on this treatment (**Figure 1B**). Tralokinumab was discontinued resulting in resolution of EAC (**Figure 1C**). Her pre-existing prurigo nodularis requires ongoing management.

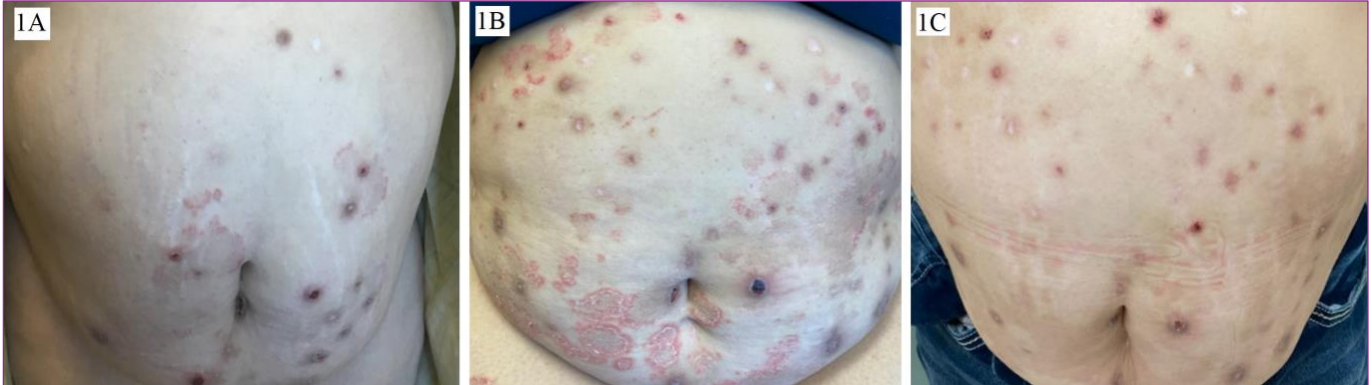## DISCUSSION

EAC is defined as a reactive erythema which typically presents as annular urticarial papules and plaques which enlarge centrifugally and clear centrally with or without a fine trailing scale inside the advancing edge. Lesions may be localized or generalized and typically occur on the trunk and extremities. It can be associated with a variety of underlying conditions including autoimmune diseases and malignancies.<sup>6</sup> EAC has been reported with the use of various drugs including diuretics, antimalarials, nonsteroidal anti-inflammatories, rituximab, ustekinumab, and more.<sup>7</sup>

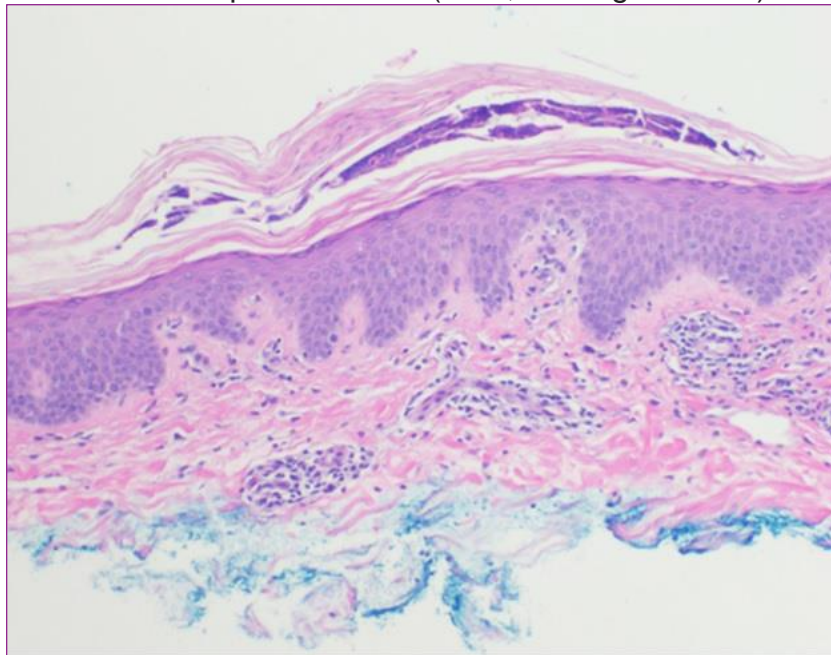
The differential diagnosis for annular plaques is broad and includes tinea corporis, erythema multiforme, erythema migrans, granuloma annulare, subacute cutaneous lupus, urticaria, and paraneoplastic eruption. Clinical features distinguishing EAC from these conditions include a distinct trailing scale at the inner border, negative fungal testing, and histopathologic findings. Histopathology can differentiate between superficial and deep variants of EAC. The superficial variant, characterized by a perivascular inflammatory infiltrate resembling pseudovasculitis, is more commonly associated with hypersensitivity reactions.<sup>7</sup>

Topical corticosteroids and phototherapy may be beneficial in aiding resolution of lesions, though the lesions should resolve

**Figure 1.** **A.** Erythematous annular plaques with discrete trailing scale on the abdomen after starting treatment with dupilumab. **B.** Increasing erythematous annular plaques with prominent trailing scale on the abdomen after discontinuation of dupilumab and initiation of tralokinumab. **C.** Scattered nodules consistent with underlying prurigo nodularis and resolution of annular plaques on the abdomen after discontinuation of dupilumab and tralokinumab.



**Figure 2.** Punch biopsy from the right thigh showing superficial perivascular dermatitis with spongiosis and areas of mounded parakeratosis (H&E, 4x magnification).



spontaneously after stopping the offending agent. Partial treatment of the EAC in our case could have played a role in resolution, although patient was not adherent to her prescribed treatment regimen due to social issues. The common mechanistic pathway of dupilumab and tralokinumab is inhibition of IL-13 via blockage of IL-4R $\alpha$  and IL-13 cytokines respectively.<sup>8</sup> Given the acute

worsening of EAC after switching from dupilumab to tralokinumab in this case, it could be suggested that inhibition of IL-13 is a factor in the pathogenesis of drug-induced EAC. This warrants further investigation if additional reports are shared of EAC as an adverse effect to selective IL-13 inhibitors.

## CONCLUSION

Clinicians should be aware that EAC may be a potential adverse effect of treatment with dupilumab. The condition may initially mimic tinea corporis or other annular erythematous lesions but dependent upon KOH prep, histopathologic findings, and timing of the eruption, a diagnosis of drug-induced EAC should be considered. Should drug-induced EAC be suspected, discontinue the offending agent and observe for spontaneous resolution of lesions with supportive therapy (topical corticosteroids, topical calcipotriene, topical tacrolimus, phototherapy). Selective inhibition of IL-13 may play a role in development of EAC or worsening of EAC, but further studies on the pathophysiology of drug-induced EAC are necessary.

**Conflict of Interest Disclosures:** None

**Funding:** None

**Corresponding Author:**

Julia Barker, MD Center  
111 Colchester Avenue, Burlington VT, 05401, USA  
Phone: 802-847-4570  
Fax: 802-847-3364  
Email: [julia.barker@uvmhealth.org](mailto:julia.barker@uvmhealth.org)

**References:**

1. Weidinger S, Beck LA, Bieber T, Kabashima K, Irvine AD. Atopic dermatitis. *Nat Rev Dis Primers*. 2018;4(1):1. doi:10.1038/s41572-018-0001-z
2. Gooderham MJ, Hong HCH, Eshtiaghi P, Papp KA. Dupilumab: A review of its use in the treatment of atopic dermatitis. *J Am Acad Dermatol*. 2018;78(3 Suppl 1):S28-S36. doi:10.1016/j.jaad.2017.12.022
3. Muñoz-Bellido FJ, Moreno E, Dávila I. Dupilumab: A Review of Present Indications and Off-Label Uses. *J Investig Allergol Clin Immunol*. 2022;32(2):97-115. doi:10.18176/jiaci.0682
4. Kychygina A, Cassagne M, Tauber M, et al. Dupilumab-Associated Adverse Events During Treatment of Allergic Diseases. *Clin Rev Allergy Immunol*. 2022;62(3):519-533. doi:10.1007/s12016-022-08934-0
5. Narla S, Silverberg JI, Simpson EL. Management of inadequate response and adverse effects to dupilumab in atopic dermatitis. *J Am Acad Dermatol*. 2022;86(3):628-636. doi:10.1016/j.jaad.2021.06.017
6. McDaniel B, Cook C. Erythema Annulare Centrifugum. In: *StatPearls*. StatPearls Publishing; 2022. Accessed February 15, 2023. <http://www.ncbi.nlm.nih.gov/books/NBK482494/>
7. Meena D, Chauhan P, Hazarika N, Kansal NK, Gupta A. Aceclofenac-Induced Erythema Annulare Centrifugum. *Indian J Dermatol*. 2018;63(1):70-72. doi:10.4103/ijid.IJD\_728\_16
8. Gonçalves F, Freitas E, Torres T. Selective IL-13 inhibitors for the treatment of atopic dermatitis. *Drugs Context*. 202