

BRIEF ARTICLE

Primary Cutaneous Apocrine Carcinoma: Diagnostic and Management Difficulties of an Uncommon Neoplasm

Mounia Sidki, MD¹, Maryem Aboudourib, MD¹, Maryam El Ouazzani, MD², Anass Belbachir, MD², Hanane Rais, MD², Yassine Benchamkha, MD³, Ouafa Hocar, MD¹, Said Amal, MD¹

¹ Department of Dermatology and Venerology, Mohammed VI University Hospital, Marrakech, Morocco

² Department of Histopathology, Mohammed VI University Hospital, Marrakech, Morocco

³ Department of Plastic surgery and burns, Mohammed VI University Hospital, Marrakech, Morocco

ABSTRACT

Primary cutaneous apocrine carcinoma (PCAC) is a rare adnexal neoplasm. Due to its clinical presentation, it can mimic other tumors, especially metastasis. We present a case of primary apocrine carcinoma of the axilla mimicking breast carcinoma metastasis in a 54-year-old woman. The patient presented with a painless, lobed, and erythematous nodule in the left axilla of one year duration. We suspected an adnexal neoplasm but also considered metastasis from breast carcinoma. Histological examination revealed apocrine proliferation. Immunohistochemistry stains of tumor cells were positive for AE1/AE3, and negative for CK7, CK20, p63 and GATA3. Radiological explorations did not reveal any signs of malignancy. Considering all these features, the conclusive diagnosis was primary cutaneous apocrine carcinoma. Treatment was wide excision without adjuvant therapy, and no recurrence was noted. Due to the rarity of this carcinoma, its various clinical presentations, and histological overlaps with breast cancer metastasis, making the diagnosis may be challenging. A comprehensive evaluation of all findings is necessary to rule out other tumors. There is any consensus on the management strategy. The standard treatment is surgical excision, but adjuvant therapies such as radiotherapy or chemotherapy can be proposed in advanced stage disease.

INTRODUCTION

Primary cutaneous apocrine carcinoma (PCAC) is a rare adnexal neoplasm that has been reported in approximately 200 cases.¹ It is an indolent and slowly growing tumor that occurs mainly in the axilla, due to a high concentration of apocrine glands.² As the clinical presentation is not specific, PCAC is difficult to differentiate from metastatic skin lesions, especially those secondary to breast adenocarcinoma.³ Making a distinction

between these tumors is highly challenging because of several histological and immunophenotypical overlaps. Guidelines for diagnosis, prognosis, and treatment are still not well defined. We report a new case of primary apocrine adenocarcinoma of the axilla mimicking breast carcinoma metastasis in a 54-year-old woman.

CASE REPORT

A 54-year-old female patient, with no medical history, presented with a painless nodular lesion in the left axilla of one year duration. Clinical examination revealed a 3 x 1.6 cm lobed erythematous nodule with overlying skin ulceration (**Figure 1**) and no evidence of lymphadenopathy. The main differential diagnosis was breast cancer metastasis. Biopsy of the lesion was performed. In the pathological examination, the tumor showed glandular architecture with atypical apocrine cells and mucin production (**Figure 2**). Immunohistochemistry stains of tumor cells were positive for AE1/AE3 (**Figure 3**), and negative for CK7, CK20, p63 and GATA3. The final pathology report showed apocrine proliferation, possibly indicative of a primary sweat gland neoplasm, but it didn't exclude the possibility of a metastatic lesion. An evaluation for primary or secondary cancer was necessary. Chest and abdominopelvic CT-scan and mammography screening didn't reveal any signs of malignancy, and endoscopy of the gastrointestinal tract was normal. Considering the clinical, histopathological and radiologic features, the most likely conclusive diagnosis was primary cutaneous apocrine carcinoma. Wide excision of the tumor with a 2 cm margin was performed by the surgery department. Microscopic findings were similar to the first pathological examination, and confirmed that the carcinoma derived from the sweat gland. The patient remained on surveillance, and no recurrence was noted at 7 months after surgery.

DISCUSSION

We report a new case of primary cutaneous apocrine carcinoma (PCAC) in the axilla of a 54-year-old woman. The diagnosis was established after a thorough evaluation of clinical, radiologic and microscopic findings. PCAC is a rare adnexal neoplasm. The

prevalence is unknown because of a limited number of cases.⁴ However, considering the possibility of misdiagnosis, the current number of cases may be underreported. PCAC often affects older patients, mainly in the seventh decade, but even young patients may present with the lesion. There is no gender predilection and its cause is unknown.^{3,4} It is a subtype of sweat gland carcinoma arising in the areas of high apocrine gland density, mainly in the axilla, but it can also occur elsewhere in the skin.¹ The clinical appearance is variable, with lesions presenting as uninodular or multinodular masses of variable color, usually red or purple. The surface can be ulcerative.^{4,5} Lesions may be associated with pre-existing lesions such as naevus sebaceous.⁴ Most of these lesions present with indolent symptoms and grow slowly, which can delay diagnosis.⁶ The primary importance is to rule out other tumors particularly metastatic breast carcinoma. Some cases with signet ring cell findings have also been reported, raising concern for metastatic stomach or colorectal adenocarcinoma. PCAC can easily be confused with cutaneous metastases of breast cancer, especially in cases presenting with an axillary mass. Both cancers share similar histological and immunohistochemical characteristics, making the diagnosis even more difficult.⁷ Making the distinction requires a detailed history coupled with a thorough clinical examination, imaging studies, histopathological examination, special stains, and immunohistochemistry.⁵ The rarity of PCAC and the lack of observational studies on this tumor make it challenging to establish the treatment strategy and prognosis. There are only expert observations, and no consensus on the management.⁷ Prognostic factors have yet to be elucidated. However, the most important predictor of survival in localized disease may be lymph node status.^{1,6} The median overall survival from

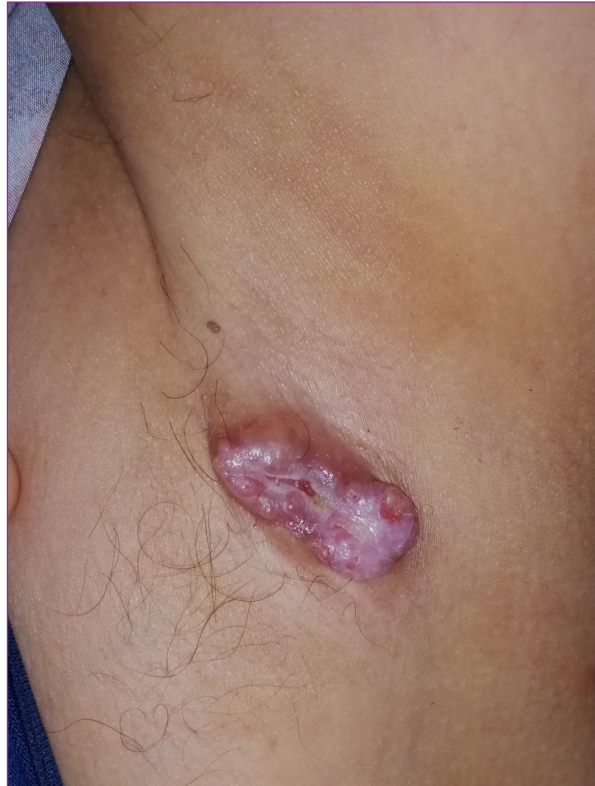

Figure 1. Reddish multi-lobed nodule with overlying central ulceration on the left axillary fold

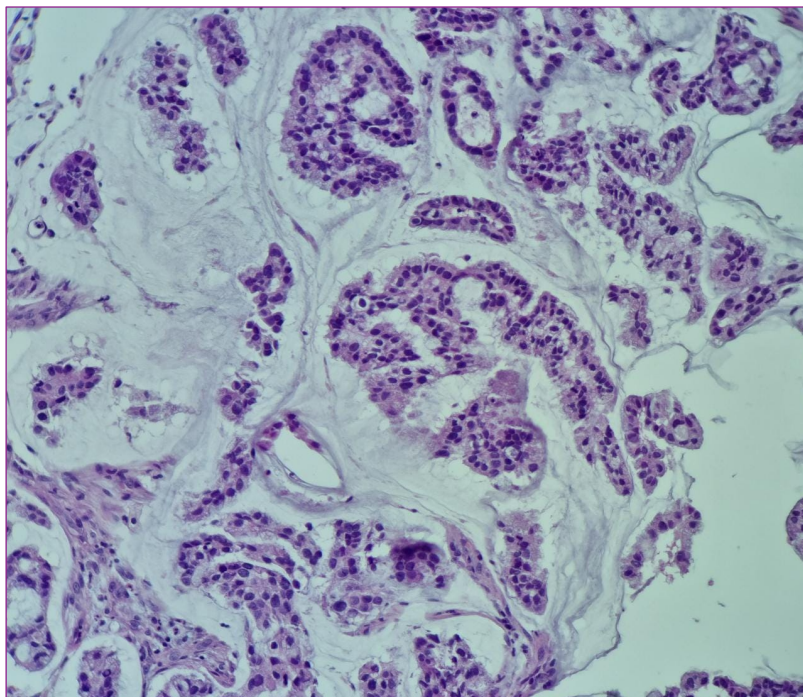


Figure 2 . Histopathology: a gland-like proliferation infiltrating the dermis consisting of atypical apocrine cells with abundant mucin production. Hematoxylin and eosin stain, magnification x200

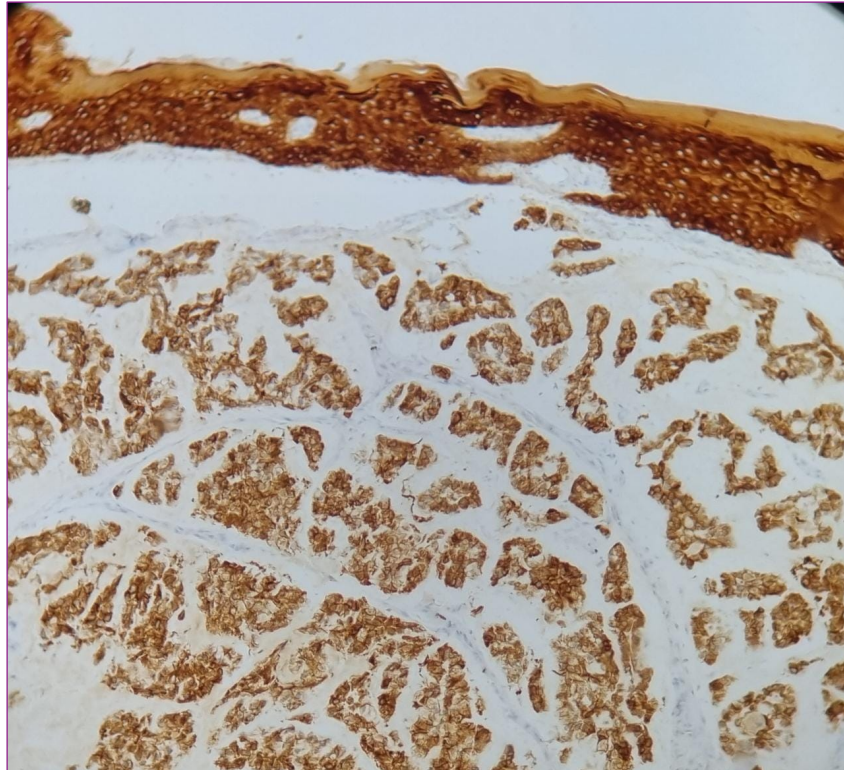


Figure 3. Immunohistochemistry: the tumor cells show strong positive staining for CK (AE1-AE3)

the most extensive retrospective series of PCAC cases was 51.5 months.³ The neoplasm can metastasize to regional lymph nodes and other organs, including lungs, liver, bone, and brain.⁸ Median survival significantly diminished following lymph node involvement and metastatic disease to 33 and 14.5 months, respectively.³ No management guidelines are available. The standard treatment is surgical excision with or without lymph node dissection. Although the surgical margin has not been standardized due to insufficient data, 1 to 2 cm can be sufficient.⁶ Usually, apocrine carcinomas have an indolent course and may achieve long term remission only with surgical treatment, particularly if the tumor is well differentiated.⁹ Radiotherapy can be an additional treatment in patients with extensive tumors or for palliation of bone and brain metastases, whereas chemotherapy, typically combinations of anthracyclines, taxanes, and platinum drugs, has been used

successfully in cases with lymph node involvement.¹⁰ Chemotherapy similar to the regimen for breast cancer has also been reported to be successful, such as epirubicin and cyclophosphamide followed by oral fluorinated pyrimidine in cases with metastatic PCAC of the axilla.⁴ The poor survival rates and limited treatment options for advanced-stage disease indicate the need for effective adjuvant treatment.

CONCLUSION

Due to the rarity and various clinical presentations of PCAC, recognizing this disease may be difficult. Metastatic lesions, especially from breast cancer, must first be ruled out, based on a careful history, radiologic, histologic, and immunohistochemical features. The recommendation for surgical excision with cleared margins seems to be appropriate for

patients with localized disease. For advanced disease, treatment guidelines must be established in order to improve the prognosis.

Conflict of Interest Disclosures: None

Funding: None

Corresponding Author:

Dr. Mounia Sidki
 Avenue Ibn Sina Amerchich · BP2360 Principal,
 Marrakech, Morocco
 Phone: +212655423701
 E-mail: mouniasidkii@gmail.com

References:

1. Z. M Brown, M. C Riesco-Martinez, T. Petrella, Treatment of primary cutaneous apocrine carcinoma of the scalp – case and review of the literature. *Global, Dermatology*. 3 (5) (2016) 356–360.
2. Choi JH, Oh HM, Kim KS, Choi YD, Joo SP, Hwang WJ, Hwang JH, Lee SY. Primary cutaneous apocrine carcinoma of the scalp: two case reports and literature review. *Medicine* 2022;101:6(e28808).
3. Hollowell K.L, Agle S.C, Zervos E.E, et al. Cutaneous apocrine adenocarcinoma: defining epidemiology, outcomes, and optimal therapy for a rare neoplasm. *J Surg Oncol*, 2012; 105(4): 415–419.
4. Płachta, I.; Kleibert, M.; Czarnecka, A.M.; Spątek, M.; Szumera-Ciećkiewicz, A.; Rutkowski, P. Current Diagnosis and Treatment Options for Cutaneous Adnexal Neoplasms with Apocrine and Eccrine Differentiation. *Int. J. Mol. Sci.* 2021, 22, 5077. <https://doi.org/10.3390/ijms22105077>
5. Crabtree M, Cheng D, Jeon C, Munteanu A, Vadehra K, Chiu R, et al. Primary cutaneous apocrine carcinoma in a 50-year-old male. *Human Pathology Reports* 2021;26:300560. <https://doi.org/10.1016/j.hpr.2021.300560>.
6. Gatti AP, Tonello L, Pfaffenzeller W, Savóia FO, Goergen DI, De Pieri Coan R, et al. Apocrine sweat gland adenocarcinoma: A rare case report and review. *International Journal of Surgery Case Reports* 2017;36:78–81. <https://doi.org/10.1016/j.ijscr.2017.04.029>.
7. Ilerhunmwuwa N, Manvar K, Wu R, Chandramouli M, Wang JC. Primary Cutaneous Apocrine Adenocarcinoma of the Axilla in Klinefelter's Syndrome: A Case Report. *Arch Breast Cancer*

- 2023:210–5. <https://doi.org/10.32768/abc.2023102210-215>.
8. Pagano Boza, C.; Vigo, R.; Premoli, J.E.; Croxatto, J.; Gonzalez Barlatay, J. A case report of a primary apocrine adenocarcinoma of the eyelid with literature review. *Orbit* 2018, 37, 389–392.
9. Chadha S, Kumar R, Singhal S, Ruhela S. Primary cutaneous apocrine carcinoma: Case report and literature review. *Indian J Pathol Microbiol* 2021;64:183-5.
10. Higaki-Mori, H.; Sugita, K.; Tsutsumi, R.; Adachi, K.; Yoshida, Y.; Yamamoto, O. Apocrine Adenocarcinoma Occurring on the Chin. *Yonago Acta Med.* 2017, 60, 64–66.