

## BRIEF ARTICLE

## A Case of Angiolymphoid Hyperplasia with Eosinophilia Treated with Combination Therapy of Topical and Intralesional Corticosteroids

Olga Marushchak, DO<sup>1</sup>, Nehal R. Shah, DO<sup>2</sup>, Mark I. Jacobson, MD<sup>3</sup>, Adriana O. Ros, DO<sup>2</sup>

<sup>1</sup> Mount Sinai Morningside-West, New York, NY

<sup>2</sup> Hackensack Meridian Palisades Medical Center, North Bergen, NJ

<sup>3</sup> Bridge Dermatopathology Services, Tarrytown, NY

### ABSTRACT

Angiolymphoid hyperplasia with eosinophilia is an uncommon, benign vasoproliferative disorder that can present with single or multiple pink to red-brown dome shaped papules, predominantly on the head and neck. The most common reported symptoms include, but are not limited to, pruritus, bleeding and pain. Currently, there is no definitive treatment for this condition, with numerous therapeutic modalities described in the literature. The most effective and commonly used treatment is excision but can be more invasive and still has a high failure rate (40.3%). Despite the high failure rates associated with topical, systemic and Intralesional corticosteroids, we were able to show significant improvement with the combination of topical and intralesional corticosteroids. This form of therapy is considerably cheaper and non-invasive compared to alternative therapies. Given the high recurrence and lack of definitive treatments, more research is needed for a better understanding of pathophysiology and identification of effective therapies.

### INTRODUCTION

Angiolymphoid hyperplasia with eosinophilia (ALHE) is an uncommon, benign, vasoproliferative disorder that typically presents as solitary or multiple pink to red-brown, dome-shaped papules and nodules, predominantly occurring in the head and neck region.<sup>1-3</sup> The rare cases of extracutaneous involvement described lesions affecting the orbit, oral mucosa, colon, and bone.<sup>4-7</sup> In 15.4% of the reported cases, the lesions were asymptomatic, while the commonly reported symptoms included pruritus (36.8%), bleeding (25.3%), and pain

(20.2%).<sup>1</sup> Additionally, a significant association was found between pruritus and bleeding and presence of multiple lesions.<sup>1</sup> Although the condition is benign, multiple monotherapy and combination therapy approaches have been attempted for symptomatic relief and cosmetic improvement. However, treatment remains challenging due to high failure rates and no definitive therapeutic options.<sup>1,8</sup> Corticosteroids are among commonly used therapies, but have been reported to have low efficacy.<sup>1</sup> In this report, we present a rare case of ALHE with positive response to the combination of topical and intralesional corticosteroids.

## CASE REPORT

A 60-year-old female presented to the outpatient clinic for the evaluation of a skin lesion on her scalp and posterior neck. The lesions first appeared three years prior and had enlarged over time. The patient also noted bleeding, itchiness, and irritation, which was aggravated by combing. Past medical history was negative for actinic keratoses, atypical or dysplastic nevi, and skin cancer. The patient denied any family history of cutaneous disorders.

On physical examination, flesh-colored nodules were distributed on the posterior neck and occipital scalp (**Figure 1**). An erythematous nodule with central erosion was noted on the left occipital scalp. A shave biopsy of the erythematous lesion was performed. Microscopic examination of the tissue revealed proliferation of small blood vessels lined by plump endothelial cells with abundant cytoplasm and accompanied by a dense inflammatory cell infiltrate containing lymphocytes and eosinophils (**Figure 2**).

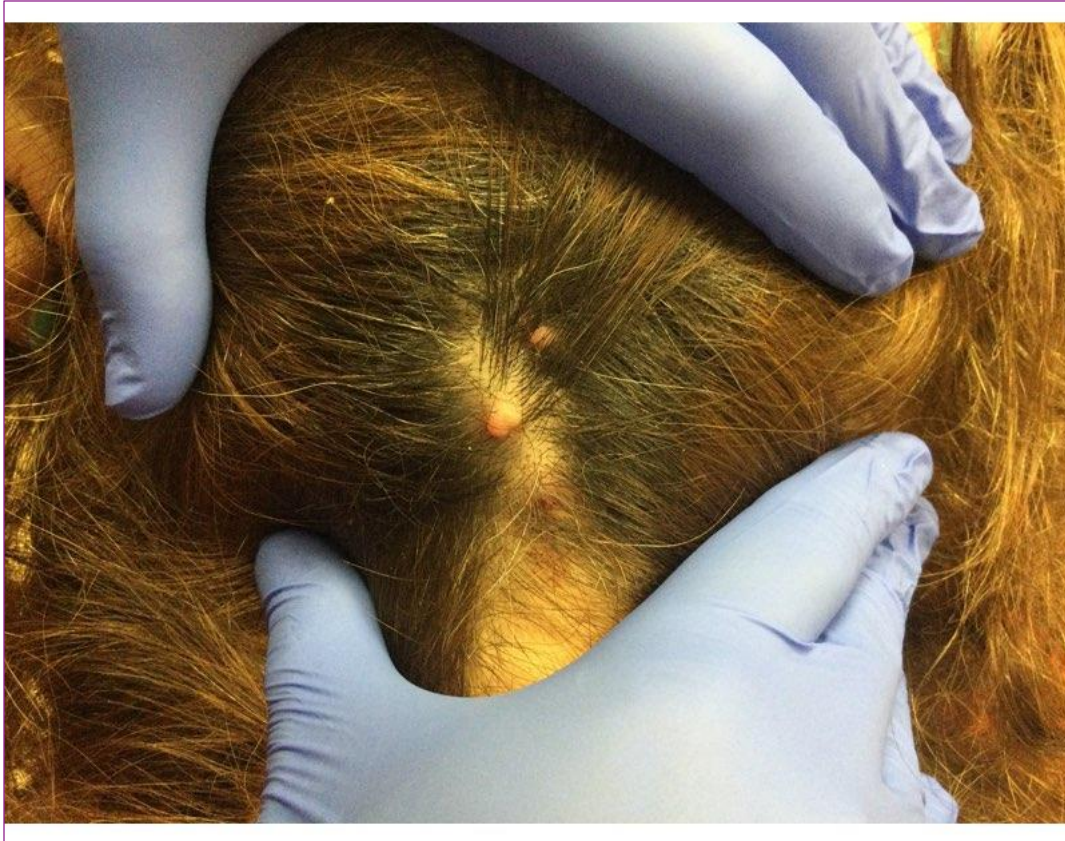
Given the clinical and histopathologic findings, the patient was diagnosed with ALHE. After discussion of therapy options, topical clobetasol 0.05% solution twice daily and intralesional triamcinolone acetonide 10 mg/mL injectable suspension once a month were initiated. Significant improvement in erythema and size of the lesions was noted after one month on the regimen. Topical corticosteroid was discontinued, while the patient is still receiving the intralesional injections monthly.

## DISCUSSION

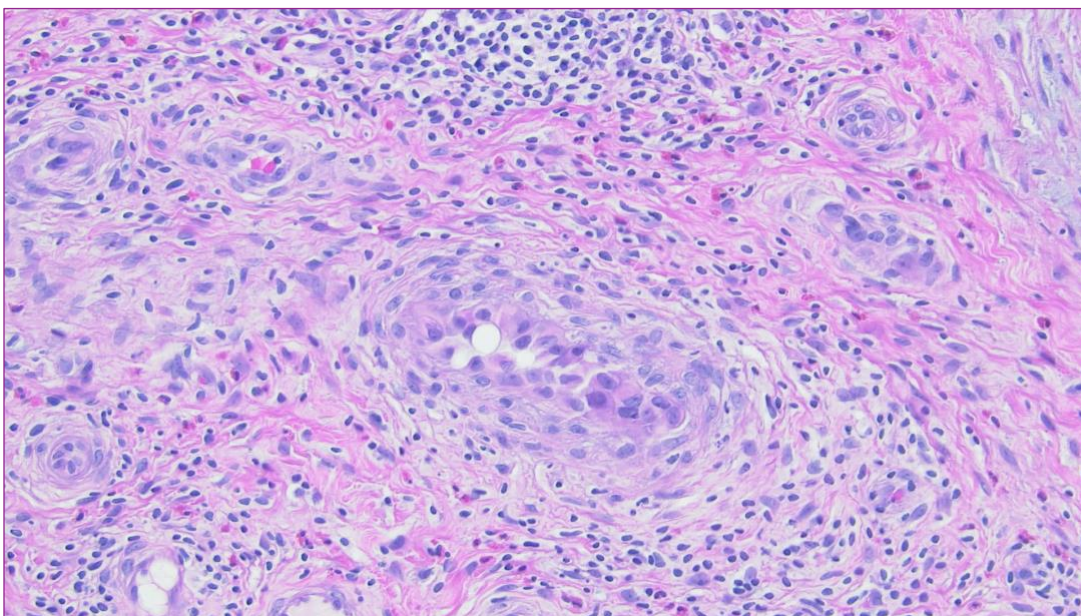
ALHE is an uncommon disorder with a poorly understood pathophysiology. The most

commonly proposed hypotheses included reaction secondary to prior trauma, infection, neoplastic vasoproliferative process, atopy, hormonal imbalance, T-cell lymphoproliferative disorder, and arteriovenous malformations.<sup>1,2,6,9,10</sup> Due to the low incidence of ALHE, poor understanding of pathogenesis, and lack of randomized clinical trials, there is no consensus on the optimal management of the patients. While numerous therapeutic approaches have been reported in the literature, including surgical excision, laser therapy, and systemic and topical medical therapies, the results remain unsatisfactory in many cases.<sup>2,3</sup> The most effective and commonly used approach is surgical excision, although the failure rate is still high (40.8%).<sup>1,3</sup> Lasers, including pulsed dye, carbon-dioxide, and argon, may target the vasoproliferative component of the disorder and were suggested as possible promising alternatives, especially in extensive cases of ALHE and poor surgical candidates.<sup>1,8</sup> With the failure rate of 50-66.7%, laser therapies still need more thorough evaluation as the evidence of their efficacy remains limited.<sup>1</sup>

Reports have also described other treatments with variable levels of success: cryotherapy, radiotherapy, photodynamic therapy, imiquimod, tacrolimus, isotretinoin, interferon alfa 2a, anti-interleukin-5 antibody, isotretinoin, and methotrexate.<sup>2,3,8</sup> Intralesional, systemic, and topical corticosteroids are commonly used therapies, despite the reported low efficacy (failure rates of 79.1%, 87.8%, and 98.2%, respectively).<sup>1</sup> However, our case report demonstrated significant improvement of ALHE with the combination of topical clobetasol solution and intralesional triamcinolone injections. This approach should be considered as an affordable non-invasive option that may offer better cosmetic



**Figure 1.** Clinical photograph of the flesh-colored nodular lesions on the occipital scalp.



**Figure 2.** Shave biopsy shows proliferation of small blood vessels lined by plump endothelial cells and a dense inflammatory cell infiltrate containing lymphocytes and eosinophils (hematoxylin and eosin stain).

results with a low risk of scarring compared to surgical excision.<sup>3</sup>

Given the high recurrence and lack of definitive treatments, there is a great need for more rigorous research to determine pathophysiology and identify effective therapy. Currently, clinicians mainly rely on case reports when managing their patients with ALHE. Thus, it is imperative to share the findings that might further our understanding of the disease and help guide the treatment plan.

**Conflict of Interest Disclosures:** None

**Funding:** None

**Corresponding Author:**

Olga Marushchak  
Mount Sinai West, 1000 10th Ave, Ste 3A-08, New York, NY 10019  
E-mail: [olga.marushchak@mssm.edu](mailto:olga.marushchak@mssm.edu)

**References:**

1. Adler BL, Krausz AE, Minuti A, Silverberg JI, Lev-Tov H. Epidemiology and treatment of angiolymphoid hyperplasia with eosinophilia (ALHE): A systematic review. *J Am Acad Dermatol*. 2016;74(3):506-12. doi:10.1016/j.jaad.2015.10.011
2. Alaidarous A, Bouissou X, Mazereeuw-Hautier J, Bulai-Livideanu C, Lamant L, Paul C. Angiolymphoid hyperplasia with eosinophilia treated with low-dose methotrexate. *JAAD Case Rep*. 2015;1(6):342-344. Published 2015 Sep 27. doi:10.1016/j.jdc.2015.08.006
3. Lembo S, Balato A, Cirillo T, Balato N. A Long-Term Follow-Up of Angiolymphoid Hyperplasia with Eosinophilia Treated by Corticosteroids: When a Traditional Therapy is Still Up-to-Date. *Case Rep Dermatol*. 2011;3(1):64-67. Published 2011 Mar 5. doi:10.1159/000323182
4. Azari AA, Kanavi MR, Lucarelli M, et al. Angiolymphoid hyperplasia with eosinophilia of the orbit and ocular adnexa: report of 5 cases. *JAMA Ophthalmol*. 2014;132(5):633-636. doi:10.1001/jamaophthalmol.2013.8243
5. Aggarwal A, Keluskar V. Epithelioid hemangioma (angiolymphoid hyperplasia with eosinophilia) in the oral mucosa. *Indian J Dent Res*. 2012;23(2):271-274. doi:10.4103/0970-9290.100439
6. Bui MM, Draper NL, Dessureault S, et al. Colonic angiolymphoid hyperplasia with eosinophilia masquerading as malignancy: a case report and review of the literature. *Clin Colorectal Cancer*. 2010;9(3):179-182. doi:10.3816/CCC.2010.n.025
7. Khanna G, Sharma S, Rajni. Angiolymphoid hyperplasia with eosinophilia involving bone. *Indian J Pathol Microbiol*. 2007;50(4):844-846.
8. Chitrapu P, Patel M, Readinger A, Menter A. Angiolymphoid hyperplasia with eosinophilia. *Proc (Bayl Univ Med Cent)*. 2014;27(4):336-337. doi:10.1080/08998280.2014.11929150
9. Stewart N, Zagarella S, Mann S. Angiolymphoid hyperplasia with eosinophilia occurring after venipuncture trauma. *J Dermatol*. 2013;40(5):393-395. doi:10.1111/1346-8138.12106
10. Zarrin-Khameh N, Spoden JE, Tran RM. Angiolymphoid hyperplasia with eosinophilia associated with pregnancy: a case report and review of the literature. *Arch Pathol Lab Med*. 2005;129(9):1168-1171. doi:10.5858/2005-129-1168-AHWEAW