

SHORT COMMUNICATION

Treatment of Cutaneous Lesions in a Case of Blue Rubber Bleb Nevus Syndrome

Sokhna Seck, MS¹, Taylor A. Bullock, MD², Shilpi Khetarpal, MD²

¹Cleveland Clinic Lerner College of Medicine, Case Western Reserve University, Cleveland, OH

²Department of Dermatology, Cleveland Clinic Foundation, Cleveland, OH

ABSTRACT

Blue rubber bleb nevus syndrome (BRBNS), sometimes called Bean syndrome, is a rare sporadic congenital vascular disorder characterized by multiple venous malformations in various organ systems, most commonly the skin and gastrointestinal tract. The presence of characteristic skin lesions is often the first suggestion of this diagnosis, though chronic anemia and intestinal bleeding are also commonly present. We report a case of a patient with painful lesions on the plantar surfaces of the feet and a new cutaneous growth on the left labia majora. The plantar lesions were treated with Nd:YAG laser and the lesion on the labia majora was removed with a shave biopsy.

INTRODUCTION

Blue rubber bleb nevus syndrome (BRBNS) is a rare vascular disorder characterized by distinct venous malformations in various organ systems. Common organ systems affected include the skin, liver, spleen, heart, eye, and central nervous system. Patients often present early in life with blue, compressible, mucocutaneous nodules that may be painful. Treatment of BRBNS is largely symptomatic; surgical interventions can be performed for symptomatic lesions.

CASE REPORT

A 27-year-old female with a history of BRBNS presented for painful lesions on the plantar surfaces of the feet (**Figure 1**) and a new growth on the left labia majora (**Figure 2**). Vascular-appearing papules on the right

lateral thigh and overlying the right scapula (**Figure 3**) were also present. She was initially diagnosed with BRBNS at the age of 15, when her pediatrician recognized the characteristic look of a few of her blue lesions and initiated further workup. Since then, vascular malformations had been found on imaging in the brain, spleen, liver, and retroperitoneum. Sclerotherapy and sirolimus had been attempted for intraabdominal vascular malformations without success, before ultimately having a liver lesion surgically removed. She also had developed many painful cutaneous lesions on the hands, legs, posterior neck, back, pelvis, and sacral area, many of which had been surgically removed. Pathology for these demonstrated venous malformations, cavernous hemangiomas, lymphangiomas and hemangiomas. The patient was instructed to undergo routine imaging to monitor for the growth of existing lesions and occurrence of new lesions. The plantar

March 2023 Volume 7 Issue 2

lesions were treated with Nd:YAG laser. The friable vascular papule on the labia majora was removed via shave biopsy, with pathology results showing a venous malformation in the setting of BRBNS.

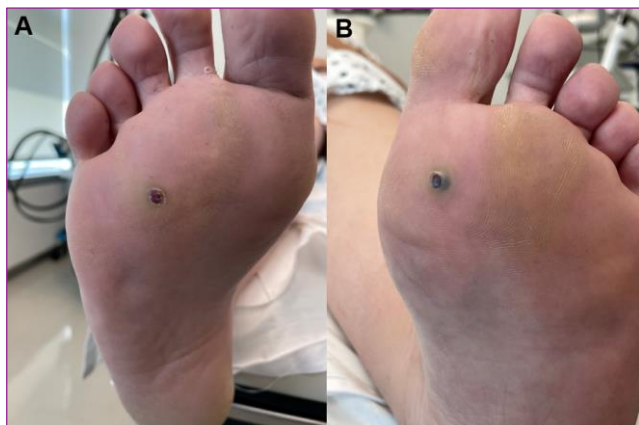


Figure 1. (A, B) Tender blue papules on the bilateral plantar surfaces of the feet.

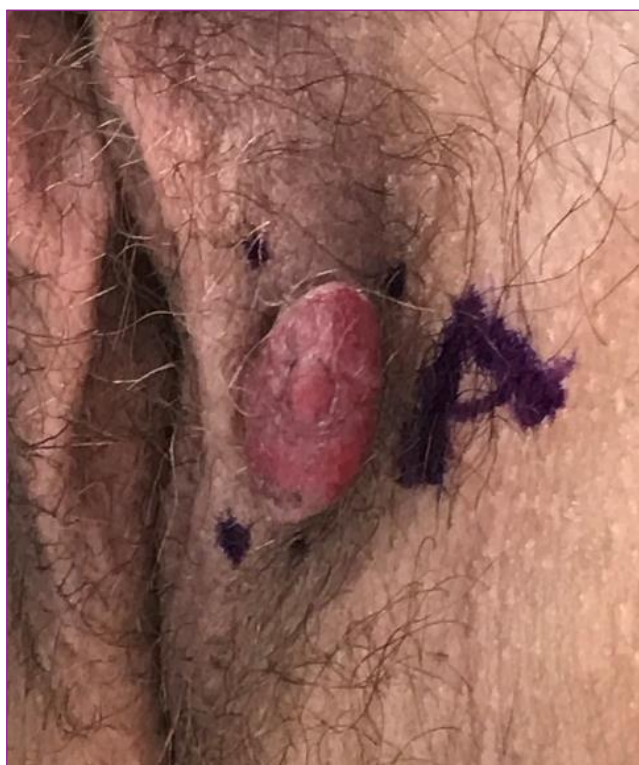

Figure 2. Venous malformation with the morphology of a friable plaque on the left labia majora.

DISCUSSION

Blue rubber bleb nevus syndrome (BRBNS), sometimes called Bean syndrome, is a sporadic congenital disorder with unknown etiology, although autosomal dominant inheritance has also been described.¹ The most commonly affected organs are the skin and the gastrointestinal tract. Intestinal bleeding and secondary iron deficiency anemia is the most common complication and the presence of skin lesions is often the first suggestion of this diagnosis in patients with chronic anemia.² All venous malformations are present at birth, though they may not be clinically apparent until later in life. Venous malformations typically cause pain due to thrombosis and can increase in size in response to trauma, thrombosis, or hormones. Management of BRBNS should involve an interdisciplinary team approach with hematology, dermatology, gastroenterology, and surgery. Iron replacement and frequent blood transfusions may be required. Symptomatic venous malformations can be treated with laser therapy, sclerotherapy, or surgical excision.

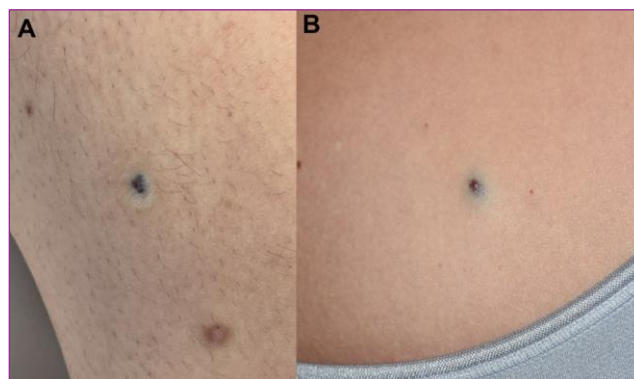


Figure 3. Blue vascular papules on the right lateral thigh (A) and overlying the right scapula (B).

CONCLUSION

BRBNS is a rare vascular disorder with venous malformations in the skin and/or internal organs. Patient education and life-long monitoring of lesions are essential. Surgical interventions, including lasers, can be used to treat cutaneous venous malformations.

Conflict of Interest Disclosures: None

Funding: None

Corresponding Author:

Sokhna Seck, MS
Cleveland Clinic Lerner College of Medicine
9501 Euclid Ave.
Cleveland, OH 44195
Email: secks@ccf.org

References:

1. Nahm WK, Moise S, Eichenfield LF, Paller AS, Nathanson L, Malicki DM, Friedlander SF. Venous malformations in blue rubber bleb nevus syndrome: variable onset of presentation. *J Am Acad Dermatol.* 2004 May;50(5 Suppl):S101-6.
2. Jin XL, Wang ZH, Xiao XB, Huang LS, Zhao XY. Blue rubber bleb nevus syndrome: a case report and literature review. *World J Gastroenterol.* 2014 Dec 7;20(45):17254-9. doi: 10.3748/wjg.v20.i45.17254. PMID: 25493043; PMCID: PMC4258599.
3. Liu Q, Chen YP, Li YM. Blue rubber bleb nevus syndrome: a report of one case associated with recurrent epistaxis. *Chin Med J (Engl).* 2007 Apr 20;120(8):731-3.