

# Therapeutic Recommendations for the Treatment of Toenail Onychomycosis in the US

Shari R Lipner, MD, PhD<sup>1</sup>; Warren S Joseph, DPM<sup>2</sup>; Tracey C Vlahovic, DPM<sup>3</sup>; Richard K Scher, MD<sup>1</sup>; Phoebe Rich, MD<sup>4</sup>; Mahmoud Ghannoum, PhD<sup>5</sup>; C Ralph Daniel, MD<sup>6</sup>; Boni Elewski, MD<sup>7</sup>

<sup>1</sup>Department of Dermatology, Weill Cornell Medicine, New York, NY; <sup>2</sup>Arizona College of Podiatric Medicine, Midwestern University, Glendale, AZ; <sup>3</sup>Temple University School of Podiatric Medicine, Philadelphia, PA; <sup>4</sup>Oregon Health and Science University, Portland, OR; <sup>5</sup>Case Western Reserve University, and University Hospitals Cleveland Medical Center, Cleveland, OH; <sup>6</sup>Department of Dermatology, University of Mississippi Medical Center, Jackson, MS; <sup>7</sup>University of Alabama at Birmingham School of Medicine, Birmingham, AL

## SYNOPSIS

- Onychomycosis—a fungal infection of the nail bed or plate—affects up to 14% of individuals in North America<sup>1,2</sup>
- It is undertreated and treatment is challenging as toenail growth can take up to 12 months or more, the nail plate may prevent drug penetration, and disease recurrence is common<sup>3-6</sup>
- National guidelines and consensus documents on onychomycosis diagnosis and treatment were last published more than 5 years ago in 2014 (British<sup>7</sup>) and 2015 (Canadian<sup>1</sup>)—around the time that both topical efinaconazole and tavaborole were first approved in the US in 2014
  - Since then, more clinical data, post hoc analyses, meta-analyses, and FDA-approved indications have become available for onychomycosis drugs
  - As such, updated medical guidance is needed

## OBJECTIVE AND METHODS

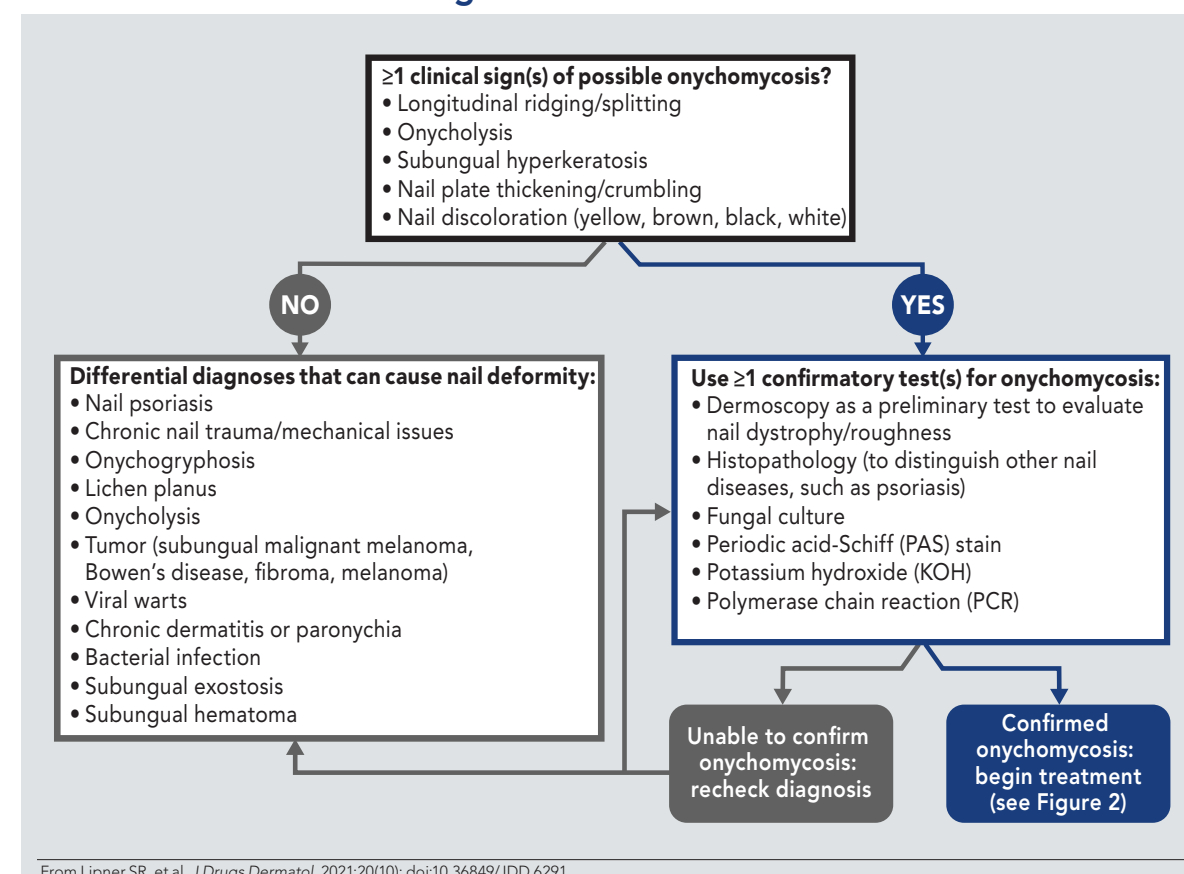
- To provide recommendations for the diagnosis and therapeutic treatment of toenail onychomycosis following a roundtable discussion with the authors on March 15, 2021
- Included here is a decision tree for choosing appropriate medications based on disease severity and patient characteristics, as well as an example handout intended for patients on best practices to mitigate disease recurrence

## RESULTS

### Diagnosis, Testing, and Clinical Presentation

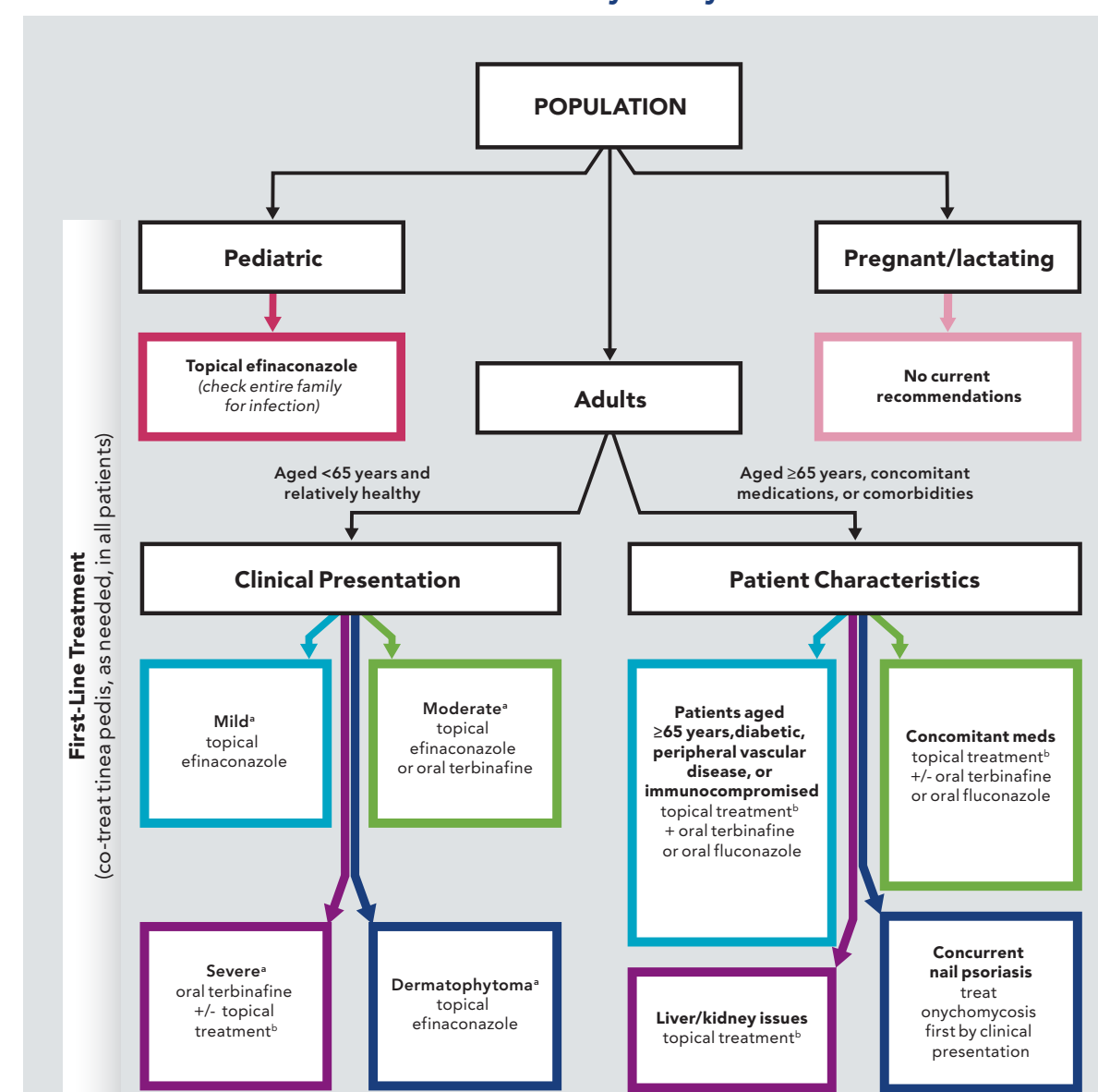
- Careful assessment and testing must be performed when diagnosing onychomycosis; nail dystrophy can be induced by other disorders, and many common conditions that can mimic onychomycosis should be ruled out (Figure 1)
- Laboratory testing should also be performed to identify the infecting organism and exclude non-fungal conditions; Figure 1 shows common options that are used in conjunction with clinical diagnosis

FIGURE 1. Differential Diagnosis Decision Tree



From Lipner SR, et al. *J Drugs Dermatol.* 2021;20(10):doi:10.36849/JDD.6291.

FIGURE 2. Decision Tree on Therapeutic Recommendations for the Treatment of Confirmed Onychomycosis



These are topline recommendations for treatment. All patient characteristics—including age, disease duration/severity, clinical presentation, concomitant medications, and comorbidities—must be taken into consideration when making treatment decisions, particularly for patients with more complex presentation. For all treatments, check prescribing information for potential drug-drug interactions and contraindications. \*Mild defined as <20% nail involvement; Moderate defined as 20%–60% nail involvement; Severe defined as >60% nail involvement and/or additional factors (ie, matrix involvement, 3 mm thickness great toenail, >1 great toenail involved, >3-4 toenails involved, total dystrophic nail). Dermatophytoma\* is a specialized term used by some dermatologists and can be defined as onychomycosis presenting as yellow or white streaks/patches in subungual space. †Eflinaconazole preferred due to higher rates of complete cure and mycologic cure versus other topical treatments. From Lipner SR, et al. *J Drugs Dermatol.* 2021;20(10):doi:10.36849/JDD.6291.

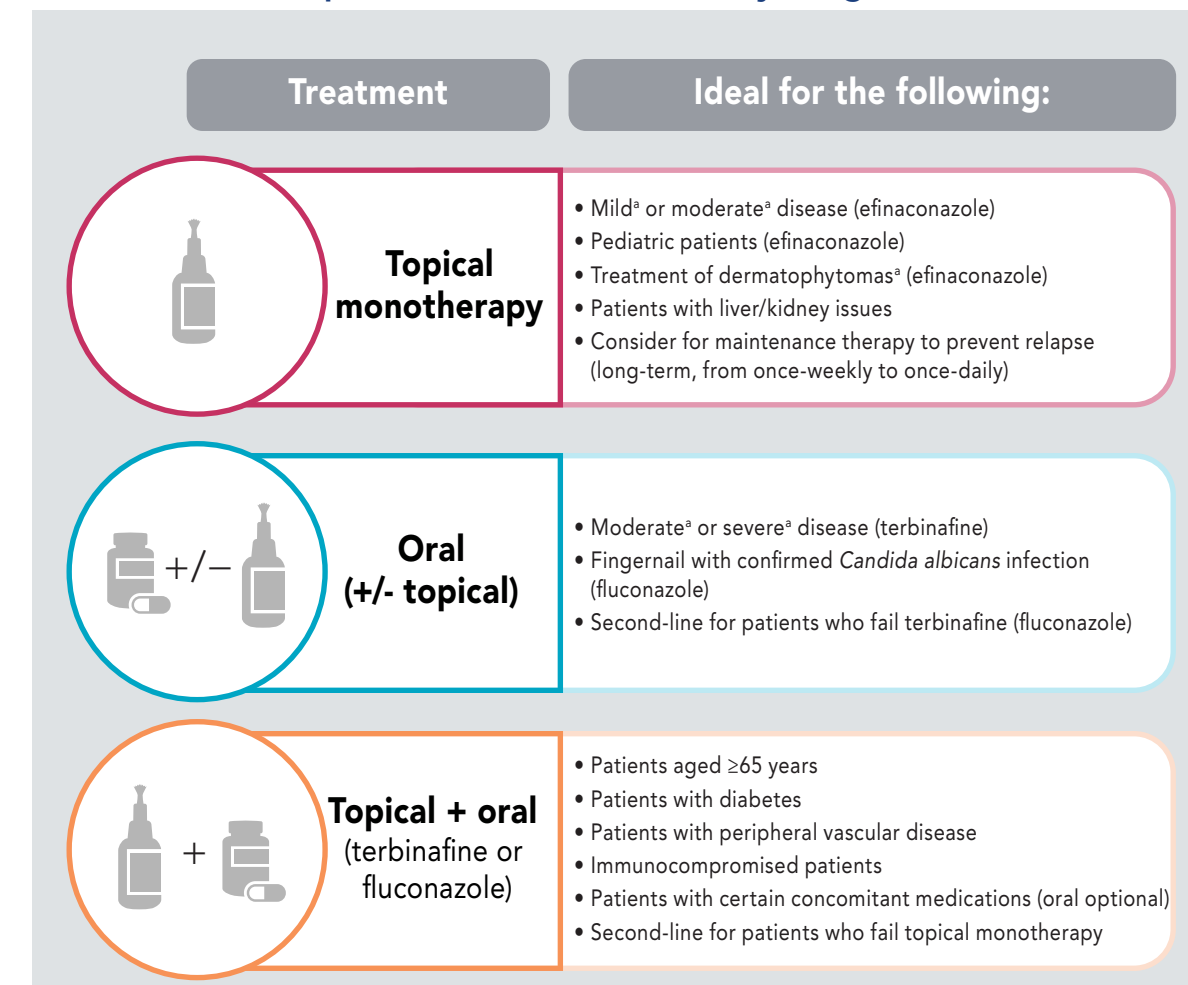
### Recommended Medications

- The authors all agreed that treatment should be individualized for each patient based on nail involvement (number, surface area, thickness), infecting organism, patient characteristics (including comorbidities), current medications, biomechanics, cost/availability/accessibility based on insurance, and patient preference
- A decision tree to provide practical guidance on therapeutic recommendations in onychomycosis treatment developed by the authors is shown in Figure 2
- Therapeutic recommendations by drug are also detailed in Figure 3
- Among oral medications, terbinafine is most commonly used as first-line treatment, followed by fluconazole
- Among topical products, efinaconazole is ideal as first-line medication in pediatric patients, patients with less severe disease, and those with dermatophytomas
- A topical medication was also recommended for use in combination with terbinafine or fluconazole and can be considered as maintenance therapy to prevent relapse
- To improve outcomes, concurrent tinea pedis should be treated in all patients receiving topical therapy for onychomycosis

### Patient Education

- It is important to manage patient expectations when treating onychomycosis: optimal results can take over a year and clinical cure/normal nail appearance may not be possible
- Patients should also be educated on the high recurrence rates (6.5%–53%)<sup>8</sup>; as such, regular follow-up visits with patients are recommended (3–6 months after oral or 1 year after topical treatment)
- A physical handout (Figure 4) should also be provided to patients, explaining follow-up care/maintenance and highlighting that long-term treatment is more than just pharmacologic (eg, personal care, footwear selection/care, laundry)

FIGURE 3. Therapeutic Recommendations by Drug



These are topline recommendations for treatment. All patient characteristics—including age, disease duration/severity, clinical presentation, concomitant medications, and comorbidities—must be taken into consideration when making treatment decisions, particularly for patients with more complex presentation. For all treatments, check prescribing information for potential drug-drug interactions and contraindications. Eflinaconazole preferred for topical treatment due to higher rates of complete cure and mycologic cure versus other topical treatments. \*See Figure 2 footnote for definitions. From Lipner SR, et al. *J Drugs Dermatol.* 2021;20(10):doi:10.36849/JDD.6291.

### CONCLUSIONS

- These therapeutic recommendations, based on new clinical data, provide important updates to previous guidelines/consensus documents to assist healthcare practitioners in the diagnosis and treatment of toenail onychomycosis
- Onychomycosis should be assessed clinically and confirmed with microscopy, histology, and/or culture
- Terbinafine is the primary choice for oral treatment and efinaconazole 10% for topical
- A topical medication was also recommended for use in combination with terbinafine or fluconazole and can be considered as maintenance therapy to prevent relapse
- For optimal outcomes, patients should be counseled regarding treatment expectations as well as follow-up care and maintenance post-treatment

FIGURE 4. Patient Education Handout

**What to know about fungal nail infections**

- Nail fungus may be in your shoes, carpet, bathroom, locker rooms, etc.
- Toenails grow slowly, so improvements could take 1–2 years to be noticeable.
- Even after the fungus is gone, the affected nail(s) may never look completely normal.
- Once the fungus is cleared, it can return.

Use treatment(s) recommended by your doctor and follow the steps below to help prevent new infections:

**Personal Care and Laundry**

- Keep nails short and clean.
- Only visit a licensed manicurist/pedicurist; bring your own tools and clean them.
- Don't pick your toenails or scratch your feet with fingernails.
- Don't use the same clippers/files used on abnormal nails on normal nails.
- Don't share personal nail care instruments, soap, or towels.
- Wash and dry your hands after contact with infected feet or nails.
- Dry feet thoroughly after washing.
- Wash towels, socks, and clothes after every use. Socks and other contaminated clothing/towels should be washed at 140°F (60°C).

**Footwear**

- Wear properly sized shoes with adequate toe boxes. Avoid narrow-toed shoes or high heels. Avoid non-breathable athletic shoes.
- Don't walk barefoot in public facilities such as pools, spas, locker rooms, showers, or gyms. Wear flip flops or shower shoes.
- When trying on new shoes, always wear socks.
- Use antifungal spray or powder in your shoes and/or a UV shoe sanitizer everyday.
- Wear moisture-wicking socks or copper or silver antimicrobial socks.
- Alternate athletic shoes to allow each pair to dry thoroughly for 2–3 days between uses.
- Replace athletic shoes after 500 miles of use.

**When to contact your doctor**

- If family/household members have athlete's foot or nail infections, they should seek treatment and take precautions to prevent spread.
- If you see signs of athlete's foot or reinfection of the nail(s), contact your doctor as soon as possible.

From Lipner SR, et al. *J Drugs Dermatol.* 2021;20(10):doi:10.36849/JDD.6291.

### REFERENCES

- Gupta AK, Paquet M. *J Cutan Med Surg.* 2015;19(3):260-273.
- Ghannoum MA, Hujeh RA, Scher R, et al. *J Am Acad Dermatol.* 2003;49(4):641-648.
- Rosen T, Friedlander SF, Kirack L, et al. *J Drugs Dermatol.* 2015;14(3):223-233.
- Gupta AK, Sen N. *F1000Res.* 2019;8.
- Tosti A, Elewski BE. *Skin Appendage Disord.* 2016;2(1):283-87.
- Narasimha Murthy S, Wiskirchen DE, Bowers CP. *J Pharm Sci.* 2007;96(2):305-311.
- Ameen M, Lear JT, Madan V, et al. *Br J Dermatol.* 2014;171(5):937-958.
- Burkhardt CN, Burkhardt CG, Gupta AK. *J Am Acad Dermatol.* 2002;47(4):629-631.
- Roberts DT, Evans EG. *Br J Dermatol.* 1998;138(1):189-190.
- Wang C, Carrnell W, Canavan T, Elewski B. *Skin Appendage Disord.* 2019;5(3):304-308.

### AUTHOR DISCLOSURES

Shari R Lipner has served as a consultant for Ortho Dermatologics, Hoth Therapeutics, and Verica. Warren S Joseph has served as consultant and speaker for Ortho Dermatologics. Tracey C Vlahovic has served as investigator and speaker for Ortho Dermatologics. Richard K Scher has nothing to disclose. Phoebe Rich has received research and educational grants from AbbVie, Allergan, Anacor Pharmaceuticals, Boehringer Ingelheim, Cassiopeia, Dermira, Eli Lilly, Galderma, Janssen Ortho Inc., Kadmon Corporation, LEO Pharma, Menzies, Midberg Derm, Novartis, Pfizer, Ranbaxy Laboratories Limited, Sanofi, Viamer Pharmaceutical Inc., Innovation Pharmaceuticals (Cellco), and Cutanea Life Sciences. Mahmoud Ghannoum has acted as a consultant or received contracts from SynGene, Inc, Bausch & Lomb, Pfizer, and Mycovia. C Ralph Daniel has provided clinical research support to Ortho Dermatologics and owns stock in Medmetrika Pharmaceuticals. Boni Elewski has provided clinical research support (research funding to University for AbbVie, Amgen, Bio, Boehringer Ingelheim, Bristol-Myers Squibb, Celgene, Incept, LEO Pharma, Lilly, Menzies, Merck, Novartis, Pfizer, Regeneron, Sun Pharma, Ortho Dermatologics, Vanda, and as consultant (received honorarium) from Boehringer Ingelheim, Bristol Myers Squibb, Celgene, LEO Pharma, Lilly, Menzies, Novartis, Pfizer, Sun Pharma, Ortho Dermatologics, Vanda.