

BRIEF ARTICLE

The Goeckerman Regimen as an Effective Treatment Modality for Checkpoint Inhibitor Dermatoses

Nicholas Brownstone, MD¹, Daniel D. Cummins, BA¹, Jocelyn Gandelman MD¹, Tina Bhutani MD¹, Wilson Liao MD¹

¹ University of California San Francisco, Department of Dermatology, San Francisco, CA

ABSTRACT

The development of immune checkpoint inhibitors has been a major breakthrough in cancer therapy. Here, we report the effective use of the Goeckerman regimen in the treatment of an evolving immune checkpoint inhibitor dermatosis. The patient is a 67-year-old male who was diagnosed with mesothelioma in April 2015 and was started on pembrolizumab presenting with subsequent skin eruptions (psoriasiform dermatitis and bullous disease). He received eight months of Goeckerman therapy at University of California, San Francisco, Psoriasis and Skin Treatment Center. Within days of starting Goeckerman therapy, he had rapid improvement in his skin lesions along with a reduction in pruritus. The Goeckerman regimen is further discussed as a novel treatment method for checkpoint inhibitor dermatoses.

INTRODUCTION

The development of immune checkpoint inhibitors has been a major breakthrough in cancer therapy. Despite their benefits, these agents are frequently associated with cutaneous side effects¹. Here, we report the effective use of the Goeckerman regimen in the treatment of an evolving immune checkpoint inhibitor dermatosis.

and fissuring of his hands. This improved with holding pembrolizumab and use of triamcinolone ointment.

CASE REPORT

The patient is a 67-year-old male who was diagnosed with mesothelioma in April 2015 and was started on pembrolizumab (200 mg IV every 6 weeks) in October 2015 at another institution. In July 2016, he developed a non-specific rash described in oncology records as: desquamation and induration on his extremities and crusting

In August 2016 he re-started pembrolizumab. One month later, he developed an eruption described in outside oncology records as having well demarcated morphology and fissuring concerning for a psoriasiform dermatitis. Pembrolizumab was held and he was treated with 75 mg of prednisone with subsequent taper and triamcinolone ointment with partial improvement. In December 2016 his pembrolizumab was discontinued due to persistent skin rash and hospitalization for adrenal insufficiency secondary to pembrolizumab.

Approximately four months after his last dose of pembrolizumab, in April 2017, the patient first presented to University of California, San Francisco, Department of

September 2021 Volume 5 Issue 5

Dermatology given persistence of his rash. He had well defined erythematous papules and plaques with silvery scale involving approximately 20% body surface area consistent with a psoriasiform dermatitis (Figure 1).

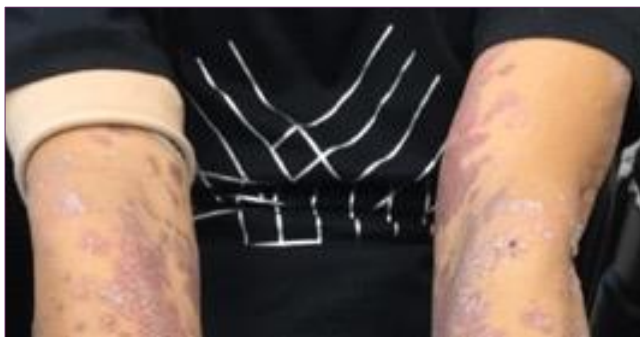

Figure 1. Presentation of psoriasiform dermatitis after 14 doses of pembrolizumab. The bilateral arms demonstrated well demarcated erythematous papules and plaques with overlying silvery scale.

A skin biopsy was obtained at this time and revealed lichenoid psoriasiform dermatitis with cytotoxicity (Figure 2).

The unique histological characteristics from this biopsy were as follows: thin band-like infiltrate of lymphocytes (some enlarged) and melanophages, and exocytosis of many lymphocytes into the surface epithelium that are coupled with scattered necrotic keratinocytes in outer epidermal layers along with a band of parakeratosis laced with serum.

The decision to start Goeckerman therapy was based on the persistence of his rash and the previous failure of topical and oral steroids.

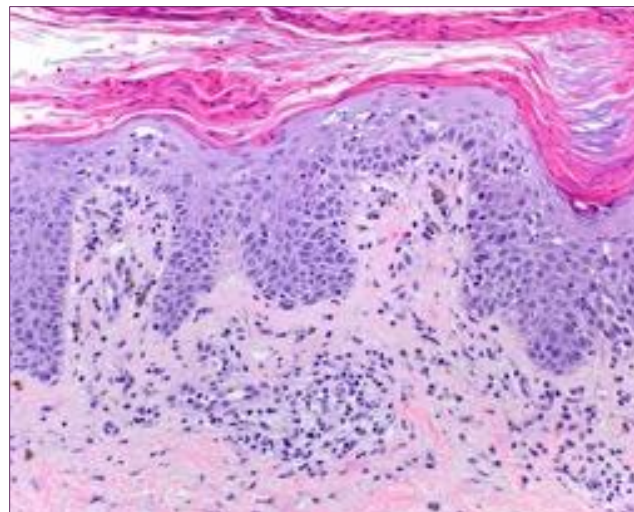


Figure 2. Psoriasiform epidermis with parakeratosis in the stratum corneum above a thin band-like infiltrate of lymphocytes and melanophages, with exocytosis of lymphocytes into the surface epithelium. A few scattered necrotic keratinocytes are noted as well in the epidermis.

He received eight months of Goeckerman therapy at University of California, San Francisco, Psoriasis and Skin Treatment Center (UCSF PSTC) which is a “day-care” outpatient phototherapy center equipped to treat patients with the Goeckerman regimen by a trained nursing staff. After eight months he noticed significant improvement with only residual plaques on his legs. However, he was also noted to have tense bullae twice, at sites unaffected by his psoriasiform dermatitis, during the treatment regimen. He was positive for bullous pemphigoid (BP) antibodies 180 and 230 on enzyme-linked immunoassay (ELISA) blood test, but his skin biopsy was negative on direct immunofluorescence (DIF). This eruption cleared with triamcinolone ointment.

He restarted Pembrolizumab in March 2020, approximately three years after his last dose, given radiologic evidence of mesothelioma progression and after six doses developed a severely pruritic eruption. The patient again presented to the

USCF PSTC in late July 2020, with generalized, pink plaques with a violaceous hue involving approximately 60% body surface area (Figure 3).

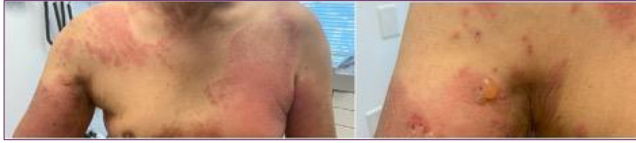

Figure 3. Well defined erythematous papules coalescing into plaques covering approximately 60% BSA with several tense bullae with serosanguinous fluid and superficial erosions atop the plaques.

There were a few scattered erosions on his back and left knee and two tense bullae filled with serosanguinous fluid on the proximal right upper arm. At this time skin biopsy showed a sub-epidermal vesicle with a few lymphocytes and eosinophils in the papillary dermis which was consistent with BP. There was also positive DIF with linear junctional deposition of IgG and C3. Bullous pemphigoid antibodies BP 180 and 230 were also positive at a higher titer than previously.

Pembrolizumab was held. He started the next day on Goeckerman therapy. This treatment was selected given his prior response to Goeckerman therapy and also to avoid a systemic agent which may have complicated his cancer treatment. Given the possible risk of precipitating bullae with phototherapy, the decision was made to first initiate a cool-down period with intense topical therapy only and to hold phototherapy.

Within days of starting Goeckerman therapy, he had rapid improvement in his skin lesions along with a reduction in pruritus. His itch level was greatly reduced from a 9 out of 10 to 1 out of 10 in this time period with sustained response. Six weeks after treatment initiation his skin was clear with no

new blisters while on Goeckerman treatment (Figure 4). He discontinued Goeckerman treatment after approximately two months total of treatment and with discontinuation had recurrence of skin blistering approximately two months later, which again resolved with Goeckerman therapy (without phototherapy). As of this writing, he has completed an additional 23 days of Goeckerman therapy with resolution of blisters and near resolution of rash.

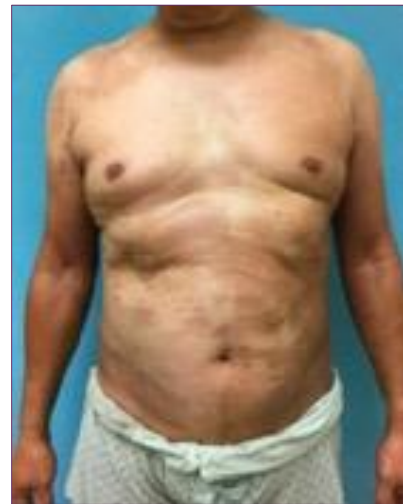

Figure 4. Six weeks after starting Goeckerman Therapy demonstrating clear skin with post-inflammatory hyperpigmentation and with no new bullae

DISCUSSION

The therapeutic use of immune checkpoint inhibitors is rapidly increasing given their unique mechanism of action and ability to treat advanced cancers. These agents include PD-1 inhibitors, such as pembrolizumab, and PD-L1 inhibitors. It is not surprising that cutaneous toxicities (irCAEs) represent one of the most frequent immune-related adverse events, as the etiology of many types of dermatitis are the result of overactive T-cells. This case is unique in that the patient developed two

different pathological morphologies (psoriasiform dermatitis and bullous pemphigoid) while on the same treatment and that the psoriasiform dermatitis, on histology, had characteristics of a cytotoxic reaction commonly seen in deficiency dermatitides and HIV-associated photodermatitis. These histological characteristics were as follows: thin band-like infiltrate of lymphocytes (some enlarged) and melanophages, and exocytosis of many lymphocytes into the surface epithelium that are coupled with scattered necrotic keratinocytes in outer epidermal layers along with a band of parakeratosis laced with serum.

There are several different methods for treating irCAEs which may depend on the severity of the presentation. Treatment for psoriasiform dermatitis induced by immune checkpoint inhibitors includes high potency topical corticosteroids, vitamin D3 analogues, narrowband ultraviolet B phototherapy, and if lesions persist, retinoids or biologics².

The Goeckerman regimen, consisting of exposure to ultraviolet B (UVB) light and application of crude coal tar (CCT), was first introduced in 1925 for psoriasis. Based on the safety and efficacy of the therapy, the Goeckerman regimen is an excellent treatment modality for any patient with moderate to severe psoriasis, eczema, and other severe pruritic and/or inflammatory skin conditions³. One case report has even successfully documented the Goeckerman regimen in the treatment of eruptive keratoacanthomas and lichenoid dermatitis due to pembrolizumab⁴. Goeckerman therapy, to the authors' knowledge, has never been reported as treating BP and a psoriasiform dermatitis due to an immune checkpoint inhibitor. Our patient rapidly improved with Goeckerman therapy which

reduced his itch level from 9 out of 10 to 1 out of 10 and cleared the erythematous plaques and papules with no new blister formation. His positive response was maintained for two months while enrolled in therapy. His blisters have recurred off therapy but have briskly responded to repeat Goeckerman therapy.

There have been a few case reports and case series regarding the development of bullous disease in psoriasis patients treated with both UVA and UVB phototherapy^{5,6,7,8,9}. In a series of 7 patients with psoriasis who subsequently developed pemphigus, 30% had been treated with phototherapy⁷. Pearson et. al. presented 3 cases of psoriasis patients presenting with BP induced by the Goeckerman regimen⁸. It is hypothesized that the reduced barrier function of the diseased psoriatic epidermis combined with the irritant effects of coal tar and UV light, together with a low-grade immunological basement membrane zone insult may precipitate blister formation in an otherwise subclinical BP process⁹. However, no clear mechanistic link or association has been described in large scale studies. Given the fact that BP may have been induced by pembrolizumab and exacerbated by UVB phototherapy, the decision was made to subsequently withhold phototherapy when the patient re-presented to Goeckerman therapy in March 2020.

CONCLUSION

In conclusion, Goeckerman therapy may present a safe, rapid and effective method for checkpoint inhibitor dermatoses.

Conflict of Interest Disclosures: None

Funding: None

Corresponding Author:

September 2021 Volume 5 Issue 5

Nicholas Brownstone, MD
 Clinical Research Fellow
 Psoriasis and Skin Treatment Center
 Department of Dermatology
 University of California, San Francisco
 515 Spruce Street
 San Francisco, CA 94118
 Email: nickbrownstone34@gmail.com

exist? *Br J Dermatol.* 1976;95(5):535-540.
 doi:10.1111/j.1365-2133.1976.tb00865.x

9. Robinson JK, Baughman RD, Provost TT. Bullous pemphigoid induced by PUVA therapy. Is this the aetiology of the acral bullae produced during PUVA treatment? *Br J Dermatol.* 1978;99(6):709-713. doi:10.1111/j.1365-2133.1978.tb07067.x

References:

1. Collins LK, Chapman MS, Carter JB, Samie FH. Cutaneous adverse effects of the immune checkpoint inhibitors. *Curr Probl Cancer.* 2017;41(2):125-128. doi:10.1016/j.currprobcancer.2016.12.001
2. Totonchy MB, Ezaldein HH, Ko CJ, Choi JN. Inverse Psoriasiform Eruption During Pembrolizumab Therapy for Metastatic Melanoma. *JAMA Dermatol.* 2016;152(5):590-592. doi:10.1001/jamadermatol.2015.5210
3. Gupta R, Debbaneh M, Butler D, et al. The Goeckerman Regimen for the Treatment of Moderate to Severe Psoriasis. *J Vis Exp.* 2013;(77). doi:10.3791/50509
4. Crow LD, Perkins I, Twigg AR, et al. Treatment of PD-1/PD-L1 Inhibitor–Induced Dermatitis Resolves Concomitant Eruptive Keratoacanthomas. *JAMA Dermatol.* 2020;156(5):598-600. doi:10.1001/jamadermatol.2020.0176
5. Albergo RP, Gilgor RS. Delayed onset of bullous pemphigoid after PUVA and sunlight treatment of psoriasis. *Cutis.* 1982;30(5):621-624.
6. Suwarsa O, Herlina L, Sutedja E, Dharmadji H, Hindritiani R, Gunawan H. Concurrence of Bullous Pemphigoid and Psoriasis: A Case Report. *Serbian Journal of Dermatology and Venereology.* 2018;10:124-128. doi:10.2478/sjdv-2018-0018
7. Zhang X, Mao X, Theresia C, et al. Pemphigus Associated with Psoriasis Vulgaris: A Retrospective Study of Seven Patients and a Review of the Literature. *Acta Dermatovenerol Croat.* 2018;26(3):226-232.
8. Person JR, Rogers RS. Bullous pemphigoid and psoriasis: does subclinical bullous pemphigoid