

BRIEF ARTICLE

IL-17A Blockade Treatment Success in Erythrodermic Pityriasis Rubra Pilaris

Wylie Masterson ,BSA¹, Daniel Morse, MD², Omar Pacha, MD²

¹ Department of Dermatology, The University of Texas Health Science Center, Houston, TX

² Department of Dermatology, The University of Texas MD Anderson Cancer Center, Houston, TX

ABSTRACT

Background: Pityriasis rubra pilaris is an inflammatory skin disease with no known etiology or treatment algorithm. PRP patients have an increase in cytokines IL-17A, IL-17F, and IL-22. There are case reports and series that study treatment with agents that block these cytokines, but more research is needed. Our objective is to add to the literature on treatment of PRP with IL-17A blockers.

Case: A 63-year-old man presented with erythrodermic pityriasis rubra pilaris that was diagnosed after biopsy and laboratory tests ruled out other conditions such as psoriasis and Sezary syndrome. He was successfully treated with IL-17 blockade.

Conclusion: Our case demonstrates the successful use of IL-17A blockade for PRP, which suggests that it could be an effective future treatment.

INTRODUCTION

Pityriasis rubra pilaris (PRP) is a rare inflammatory skin disease of unknown etiology and without a clear treatment algorithm. Lesional skin of patients with PRP demonstrates increased levels of the cytokines, IL-17A, IL-17F, and IL-22. Correspondingly, IL-17A inhibitors, such as secukinumab, has been reported to effectively treat PRP.¹ IL-23 inhibition has not been attempted in the treatment of PRP though it acts in the same inflammatory cascade.²

We present a case of new onset erythrodermic PRP successfully treated with IL-17A blockade.

CASE

A 63-year-old man with Hashimoto's thyroiditis and type 1 diabetes mellitus presented with a new onset, diffuse erythematous rash and waxy palmoplantar keratoderma. The rash began four months earlier as an erythematous patch on the patient's scalp which spread cephalocaudally to cover his entire body over the next month. He reported severe pruritus, worsening of the rash with sun exposure, and new alopecia on his parietal scalp. On presentation, he had diffuse salmon colored erythema with distinct 'islands of sparing' and significant palmar and plantar waxy keratoderma (Figure 1). The differential diagnoses included erythrodermic psoriasis, erythrodermic mycosis fungoides, Sezary syndrome,

September 2021 Volume 5 Issue 5

erythrodermic drug eruption, erythroderma secondary to malignancy, and PRP. Labs revealed 19% eosinophils and a

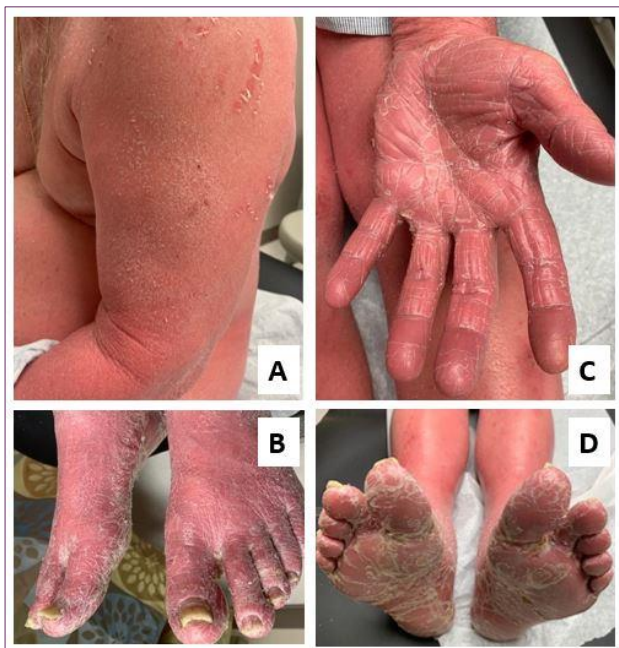

Figure 1. A) Pictured is the patient's red orange (salmon) colored erythema and fine flaky scaling involving 95% of his body surface **B)** There is bilateral toenail and fingernail plates with yellowing, thickening, subungual debris and onycholysis with no pitting **B-D)** There is evident palmar-plantar hyperkeratosis and waxy keratoderma.

normal white blood cell count. Skin biopsy revealed vertical and horizontal alternating orthokeratosis and parakeratosis. A thickened granular layer, short thicker rete ridges, and limited vascular dilation in the dermal papillae were seen. (Figure 2). T-cell receptor testing revealed no abnormal gene rearrangements and flow cytometry failed to reveal aberrant cells. These features were considered compatible with PRP.

The patient originally presented to an outside dermatologist one month after the rash began who started the patient on acitretin 25 mg in the morning and 17.5 mg in the evening, hydroxyzine 25 mg, and 0.1% triamcinolone ointment. Two months

after rash presentation, he was started on risankizumab with an initiation dose of 150 mg at week 0 and week 4. This was followed by maintenance dosing of 150 mg every three months. After three months of no improvement while on risankizumab and four months since the rash began, he presented to our institution. We discontinued the risankizumab, increased his acitretin to acitretin 25 mg twice daily, and continued the 0.1% triamcinolone ointment wet wraps. Later that month we started him on secukinumab with an initiation dose of 300 mg injections weekly for the first four weeks and then monthly thereafter for maintenance.

Two months after initiating secukinumab his pruritus and skin discomfort had improved but his erythroderma was persistent. Two months after improvement on the secukinumab, methotrexate was added as an additional therapy, and his acitretin was stopped. Three months later, he had nearly complete resolution of his erythroderma, keratoderma, scaling, and pruritus. At last follow-up seven months after starting the secukinumab and five months after starting the methotrexate, he is stable and will remain on both treatments.

DISCUSSION

PRP is a rare inflammatory skin disease with no known etiology and no established treatment algorithm.³ It typically presents with salmon colored diffuse erythema with distinct 'islands of sparing', that starts on the head or neck and then spreads cephalocaudally. Other features include follicular hyperkeratosis, irregular hyperpigmentation, palmar and plantar waxy keratoderma, and pruritus. Nail findings in PRP can include subungual hyperkeratosis, yellow discoloration, nail plate thickening,

splinter hemorrhages and the absence of

nail

pitting.³

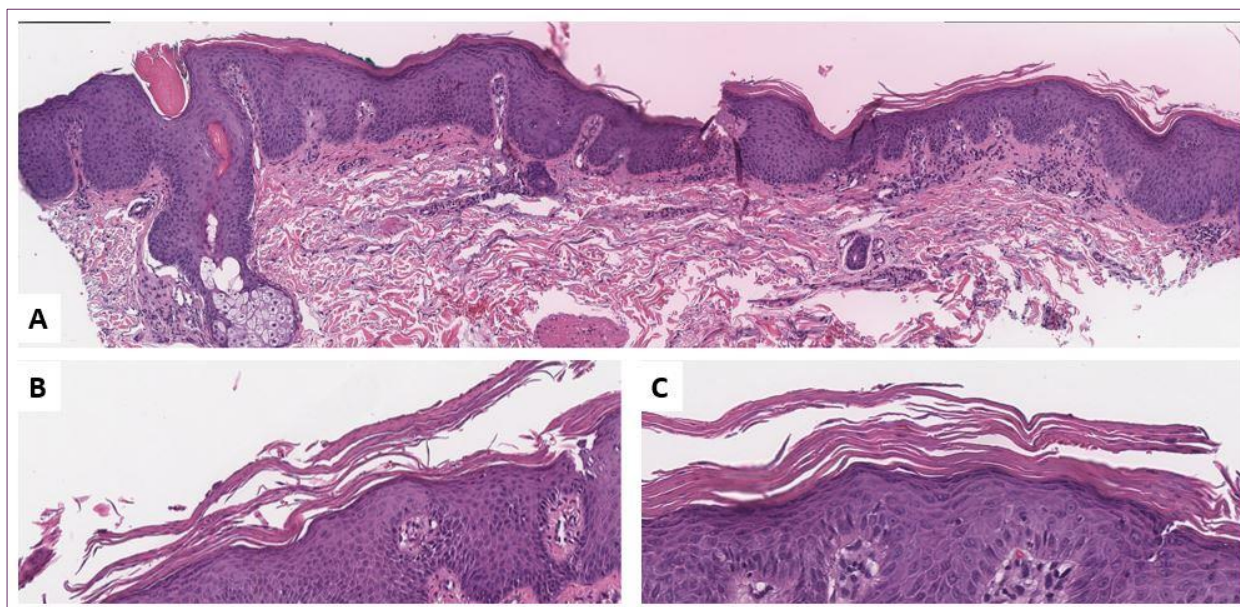


Figure 2. A-C) Moderately acanthotic epidermis with alternating hyperkeratosis and parakeratosis and retention of the granular layer **A)** Mild lymphocyte exocytosis was noted as well as a mild superficial perivascular lymphohistiocytic inflammatory infiltrate.

Histologically, PRP is marked by irregular acanthosis, alternating vertical and horizontal orthohyperkeratosis and parakeratosis, irregular acanthosis with thickened suprapapillary plates, and preservation of the stratum granulosum.⁴

Clinically, our differential diagnoses included erythrodermic psoriasis, erythrodermic mycosis fungoides, Sezary syndrome, and erythrodermic drug eruption. PRP and erythrodermic psoriasis are frequently mistaken for each other. A helpful clue in distinguishing the entities is the presence of nail pitting, which is expected in psoriasis, but not in PRP. Additionally, PRP exhibits a waxy keratoderma or “carnauba wax” appearance of the palms and soles that is not present in psoriasis.

In our case, erythrodermic mycosis fungoides was unlikely based on histology, and there was no abnormal T-cell gene

rearrangement. T-cell receptor testing revealed no abnormal gene rearrangements and flow cytometry failed to reveal aberrant cells which excluded Sezary syndrome. Finally, no new medication or medication changes made erythrodermic drug eruption unlikely.

Interestingly, in skin lesions of PRP patients, studies found an upregulation of helper T-cell 17 cytokines including IL-17A, IL-17F, and IL-22,⁵ which suggests that the IL-23-Th17 pathway plays an important role in this condition. IL-23 helps activate Th17 cells by contributing to JAK and Tyr-residue phosphorylation. This phosphorylation causes an increase in IL-17A, IL-17F, tumor necrosis factor, and IL-6 production as well as an increase in keratinocyte proliferation.⁶ These cytokines are targets of therapies including IL-23 and IL-17 inhibitors which are now being used to treat skin diseases such as psoriasis and PRP.⁷ Secukinumab, a human IgG1 anti-IL17A antibody,

selectively binds to IL-17A cytokines. This prevents binding of the cytokine to its receptor, which inhibits the release of proinflammatory cytokines from Th-17 cells.^{7,11} The inhibition of IL-17 can lead to successful treatment of PRP, which is shown in previous case reports, series, and review articles.^{2, 8-10}

CONCLUSION

In conclusion, we present a case of PRP that was successfully treated with secukinumab and methotrexate. The patient was not on risankizumab for long enough to determine its effect. This case is limited by the natural course of PRP, so it impossible to know whether our treatment led to his resolution – his treatment has not yet been held. However, our report adds to the body of literature suggesting IL-17 inhibition as effective treatment for PRP which supports the research on the IL-23-Th17 pathway in PRP.

Conflict of Interest Disclosures: None

Funding: None

Corresponding Author:

Daniel Morse MD,
Department of Dermatology,
The University of Texas Health Science Center
1400 Pressler St,
Houston, TX 77030
Phone: (713)563-1665
Fax: (713)745-3597
E-mail: Daniel.c.morse@uth.tmc.edu

References:

1. Wain T, Secukinumab in pityriasis rubra pilaris: A case series demonstrating variable response and the need for minimal clinical datasets. *JAAD Case Rep.* 2018
2. Brembilla, Nicolo Costantino, Luisa Senra, and Wolf-Henning Boehncke. "The IL-17 Family of Cytokines in Psoriasis: IL-17A and

- Beyond." *Frontiers in immunology* 9 (2018): 1682–1682. Web.
3. SONNEX, T. S et al. "The Nails in Adult Type 1 Pityriasis Rubra Pilaris: a Comparison with Sézary Syndrome and Psoriasis." *Journal of the American Academy of Dermatology* 15.5 (1986): 956–960. Print.
4. Brown F, Badri T. Pityriasis Rubra Pilaris. [Updated 2020 Jun 29]. In: StatPearls [Internet]. Treasure Island (FL): StatPearls Publishing; 2020 Jan-.
5. Feldmeyer, Laurence et al. "Interleukin 23–Helper T Cell 17 Axis as a Treatment Target for Pityriasis Rubra Pilaris." *JAMA dermatology (Chicago, Ill.)* 153.4 (2017): 304–308. Web.
6. Liu, Taoming et al. "The IL-23/IL-17 Pathway in Inflammatory Skin Diseases: From Bench to Bedside." *Frontiers in immunology* 11 (2020): 594735–594735. Web.
7. Wasilewska A, Winiarska M, Olszewska M, Rudnicka L. Interleukin-17 inhibitors. A new era in treatment of psoriasis and other skin diseases. *Postepy Dermatol Alergol.* 2016;33(4):247- 252. doi:10.5114/ada.2016.61599
8. Schuster D, Pfister-Wartha A, Bruckner-Tuderman L, Schempp CM. Successful Treatment of Refractory Pityriasis Rubra Pilaris With Secukinumab. *JAMA Dermatol.* 2016;152(11):1278–1279. doi:10.1001/jamadermatol.2016.3885
9. Schuster, Daniel et al. "Successful Treatment of Refractory Pityriasis Rubra Pilaris With Secukinumab." *JAMA dermatology (Chicago, Ill.)* 152.11 (2016): 1278–1279. Web.
10. Wu, Kevin K, and Harry Dao. "Off-Label Dermatologic Uses of IL-17 Inhibitors." *The Journal of dermatological treatment ahead-of-print.* ahead-of-print 1–7. Web.
11. Fala L. Cosentyx (Secukinumab): First IL-17A Antagonist Receives FDA Approval for Moderate-to-Severe Plaque Psoriasis. *Am Health Drug Benefits.* 2016;9(Spec Feature):60-63.