

# Photodynamic therapy with BF-200 ALA for the treatment of mild to severe actinic keratosis on extremities and trunk/neck:

## Results of a randomized Phase III trial

Authors: T. Dirschka<sup>1</sup>, M. Ulrich<sup>2</sup>, U. Reinhold<sup>3</sup>, R. Dominicus<sup>4</sup>, R. Aschoff<sup>5</sup>, R.-M. Szeimies<sup>6</sup>

Institutes: <sup>1</sup> CentroDerm GmbH, Wuppertal, Germany and Faculty of Health, University Witten-Herdecke, Witten, Germany; <sup>2</sup> CMB Collegium Medicum Berlin GmbH, Berlin, Germany, <sup>3</sup> MVZ Dermatologisches Zentrum Bonn GmbH, Bonn, Germany, <sup>4</sup> ProDerma, Dülmen, Germany, <sup>5</sup> Department of Dermatology, University Hospital Carl Gustav Carus, Technical University Dresden, Dresden, Germany, <sup>6</sup> Department of Dermatology and Allergology, Klinikum Vest GmbH, Recklinghausen, Germany



### Synopsis

BF-200 ALA is a gel containing 5-aminolevulinic acid hydrochloride (10%) in a nanoscale lipid vesicle formulation. It is approved under the brand name Ameluz<sup>®</sup> for lesion- and field-directed AK treatment on face and scalp in the US and for treatment of mild to moderate AK on face and scalp and superficial and nodular basal cell carcinoma (BCC) in the EU. We herein report the results of a randomized Phase III trial investigating BF-200 ALA in combination with red light for the treatment of mild to severe AK on extremities and trunk/neck.

### Trial protocol - actinic keratosis

#### Objectives

- The pivotal Phase III study (EudraCT 2017-000486-72) was performed to characterize the efficacy and safety profile of BF-200 ALA compared to placebo in the treatment of mild to severe AK lesions located on the extremities and trunk/neck with PDT when using the BF-RhodoLED<sup>®</sup> lamp, a narrowband, red light illumination source.

#### Medication

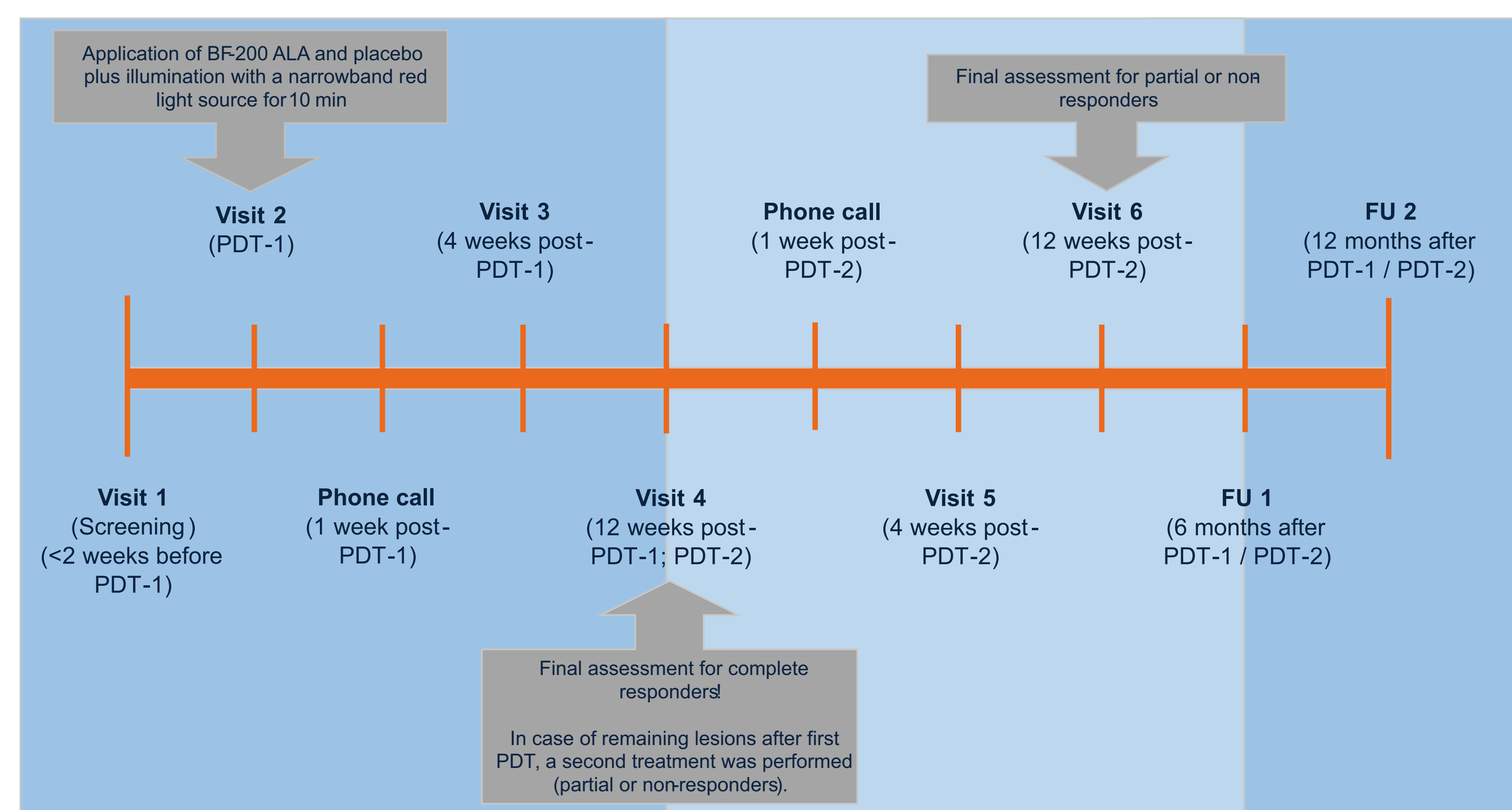
- BF-200 ALA gel (contains 10% ALA hydrochloride equivalent to 7.8% 5-aminolevulinic acid (ALA))
- Placebo to BF-200 ALA gel

#### Patients & treatment procedure

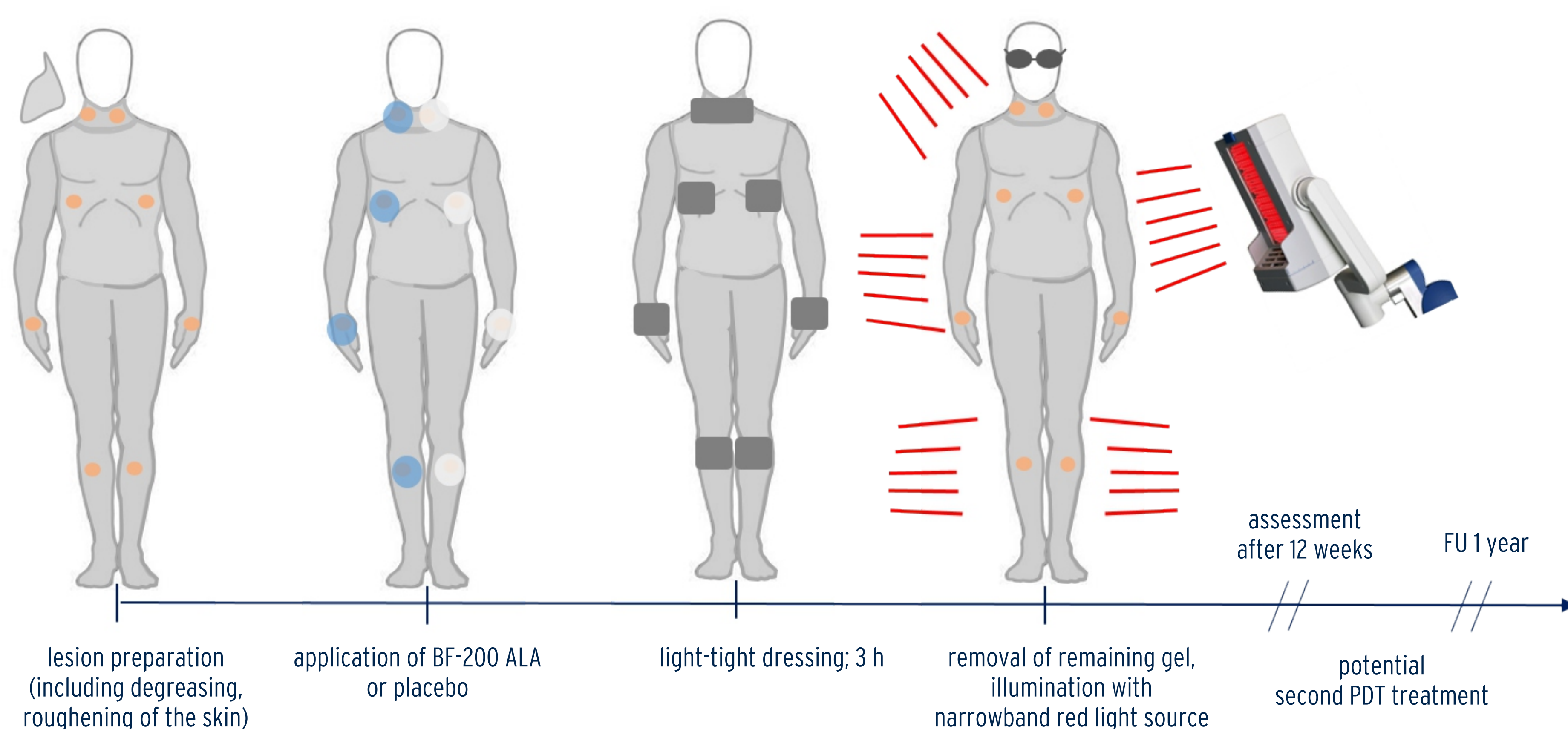
- Randomized, double-blind, intra-individual Phase III trial was performed in 6 sites in Germany
- 50 patients with clinically mild to severe AK lesions on the extremities and trunk/neck were treated after randomization
- Illumination was performed 3h after drug application for 10 min with a narrowband red light source (~635 nm, 37 J/cm<sup>2</sup>)
- In case of remaining lesions after first PDT, a second treatment was performed 12 weeks after PDT-1
- Follow-up (FU): 6 and 12 months

#### Endpoints

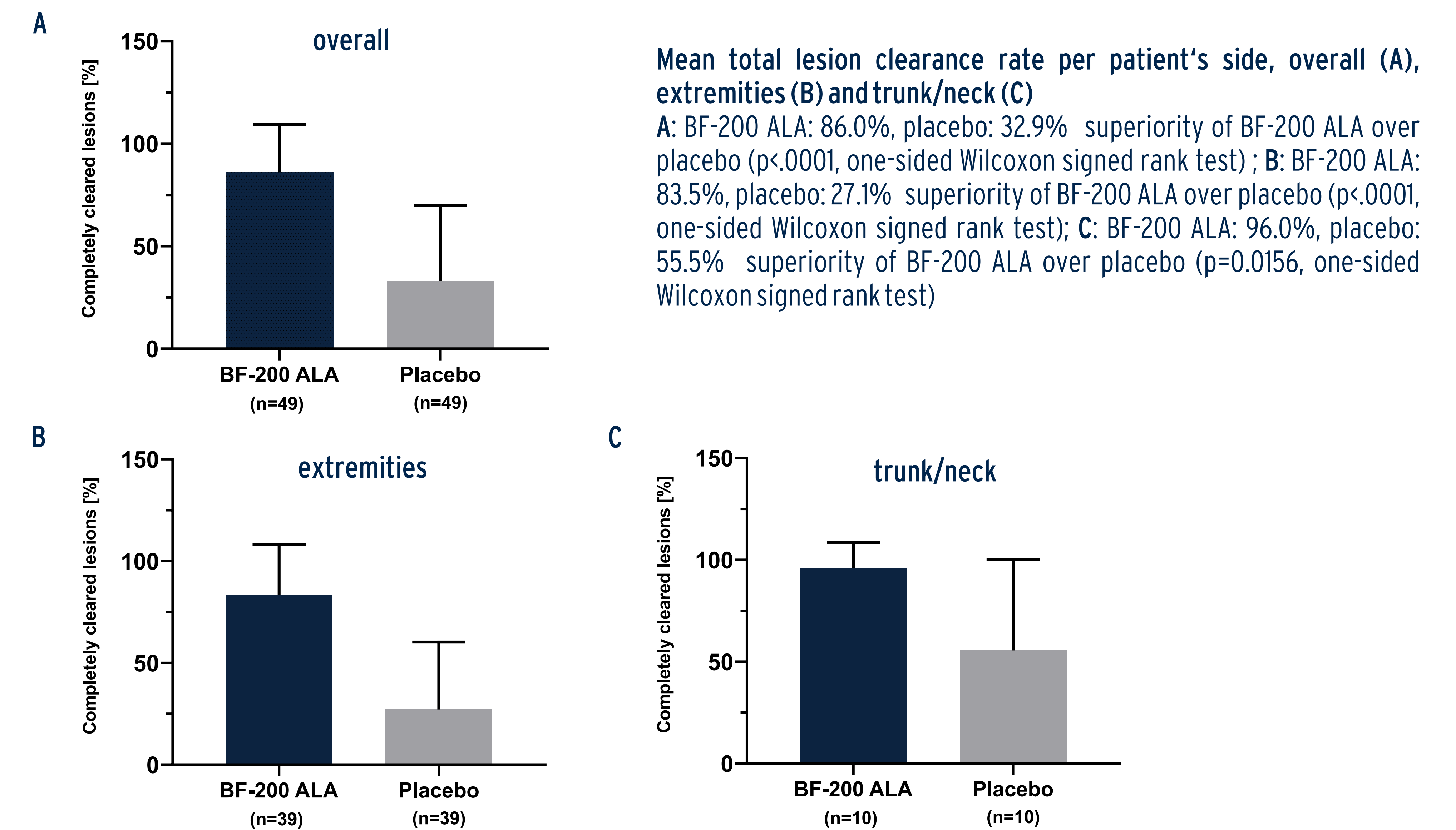
- Primary endpoint: total lesion clearance rate in percent per patient's side 12 weeks after the last PDT
- Secondary endpoints: different characteristics of lesions and the overall cosmetic outcome



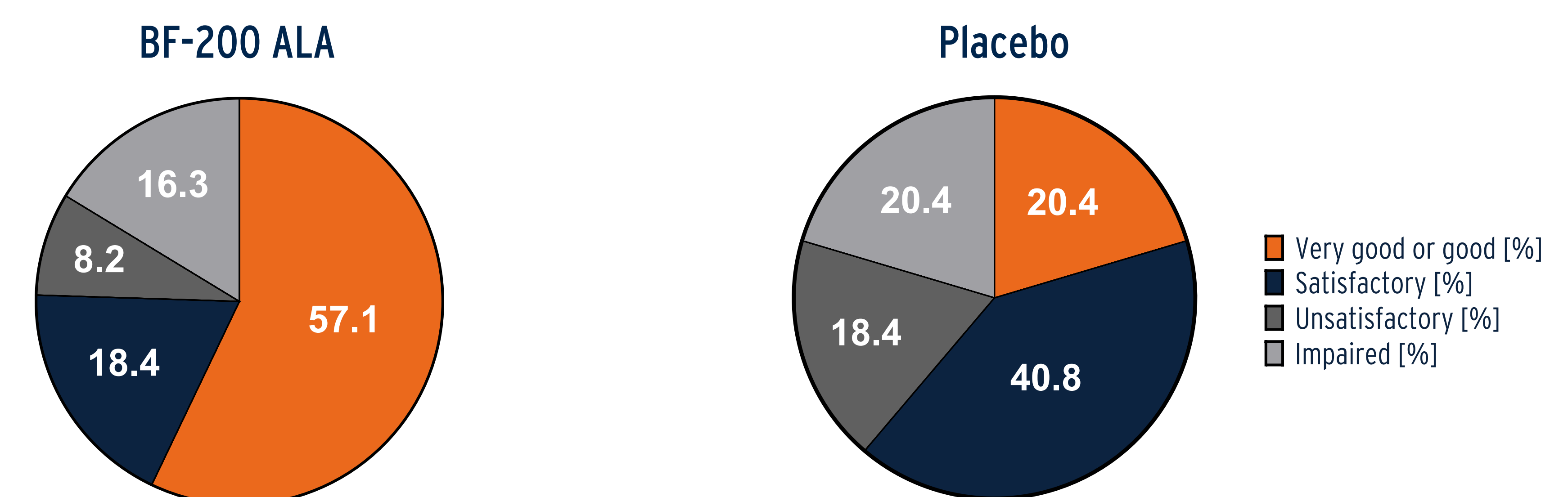
### Schematic overview: PDT for AK treatment on extremities and trunk/neck



### Total lesion clearance per patient's side - 12 weeks after the last PDT



### Overall cosmetic outcome 12 weeks after the last PDT [FAS]



### Overview of adverse events

Due to ALA PDT's mode of action, AEs are mainly local application site reactions such as erythema, pain, edema, and irritation which are transient and self-limiting, normally within 1-2 weeks.

N=50	Treated side of extremities or trunk/neck			
	BF-200 ALA	Placebo	Not allocated to a specific patient's side	side unknown
Any AEs	50 (100)	28 (56.0)	22 (44.0)	5 (10.0)
Any serious AEs	2 (4.0)	0	3 (6.0)	0
Any TEAEs	50 (100)	28 (56.0)	20 (40.0)	5 (10.0)
Any serious TEAEs	2 (4.0)	0	2 (4.0)	0
Any TEAEs leading to death	0	0	0	0
Any related TEAEs	50 (100)	22 (44.0)	1 (2.0)	0
Any TEAEs resulting in discontinuation of study	0	0	0	0

SAF: Safety Analysis Set; AE: adverse event; TEAE: treatment-emergent adverse event

### Conclusions

- High efficacy for AK treatment on extremities, trunk and neck: superiority of BF-200 ALA over placebo
- PDT with BF-200 ALA is well-tolerated
- Overall cosmetic outcome of PDT with BF-200 ALA is superior over placebo (p<.0001, one-sided Wilcoxon signed rank test)

